



NESA Days 2006 – Optimizing Endoscopy

Concise conference report

Hilton Hotel Berlin - January 19-21, 2006 - www.nesa-days.com

The NESA Days 2006 started on Friday evening (January 19) with a festive Get-Together accompanied by live songs of Marlene Dietrich. The conference was officially opened on Saturday morning with greeting words of Dr. Francesco De Meo, Director of the NESA, Prof. h.c. Dr. Michael Stark, President of the NESA, Prof. Dr. Albert Vetter, President of the German Association of Obstetrics and Gynaecology, Prof. Dr. Oktay Kadayıfçı, President of the Turkish Society of Perinatology and NESA's representative in Turkey, and Prof. Dr. Svend Schulze, President of the Danish Surgical Society. All speakers stressed the importance of interdisciplinary thinking in the field of surgery. On Saturday evening, the participants of the conference as well as diplomats and representatives of medical and local organisations enjoyed a dinner and a concert of the “Comedian Harmonists”.

During the conference, the participants had the opportunity to have a test drive on a DaVinci system. The exhibitors World of Medicine, Polydimensions, Karl Storz, BATU, Stryker, Richard Wolf, the HELIOS Research Center and the HELIOS academy presented their work or medical instruments.

The NESA Days 2006 can be considered as having been a very successful conference not only because of the quality of the lectures and of extensive exchange of ideas but also because of its international character, its 200 participants coming from 23 European and non-European countries. The feedbacks received by the organisers praised, beside the high level of the presentations, a very motivating and constructive atmosphere during the different sessions and the informal talks.

The “**NESA Days 2007, The Second Annual Scientific Meeting of the New European Surgical Academy**” will take place in Istanbul, September 1 – 3, 2007.

The scientific programme

The conference started with a plenary session. Prof. Liselotte Mettler from the University Hospital of Kiel hold a lecture about “the Past and present of gynecological endoscopy”, Prof. Farr Nezhat from the Mount Sinai Hospital in New York spoke about “Complications in laparoscopic surgery” and Dr. Albert Schaeffer reviewed the planning of surgical procedures with modern computer sciences. The lecture of Prof. Arie Admon from the Technion Institute in Haifa about “the proteome and the MHC-peptidome of human cancer cells” awoke a great interest. In the following discussion, it was suggested that Proteomics might be used in addition to histological examinations in endoscopical operations or replace them in the future.

The plenary session was followed by an interdisciplinary session with state-of-the-art lectures about the following topics: “The role of endoscopy today”, “new developments in endoscopy”, “the future of endoscopy” and “alternatives to traditional methods”. Besides these lectures, there were sessions with a specific focus, like otolaryngology, gynaecology, urology, gastroenterology, “the use of endoscopy in malignancies” and “modifications of techniques in use”. A session about “Organisation and quality management” was well visited and caused many discussions and exchanges of ideas.

A big emphasis was given to the prevention of complications in operative laparoscopy and to alternatives to endoscopical procedures such as **focused**

ultrasound for the treatment of uterine and breast tumors, the use of **cryotherapy** to reduce the size of fibroids or a modified vaginal hysterectomy (the so-called “**Ten Step Vaginal Hysterectomy**”) as a valid alternative to the endoscopic hysterectomy.

Throughout the whole conference, the emphasis was also placed on advances in technology such as the radius surgical system, the 3-dimensional “Insect Eye” laparoscopic imaging system, a computer-generated 3-dimensional animation of a surgical procedure and the Transanal Endoscopic Microsurgery (TEM). The conference ended with interdisciplinary sessions concerning creative thinking and controversial issues.

A workshop about “multimodal postoperative analgesia and recovery” chaired by anaesthesiologists from different countries showed great advances towards painless recovery and safety of endoscopical procedures. A very interesting round table demonstrated the transition from surgery to minimal invasive and non-invasive procedures.

The main message of this endoscopical conference is that Endoscopy, vaginal and rectal approaches are going to replace Open Surgery in the next years. It seems that the only laparotomy of the future will be the cesarean section.

The interdisciplinary character of the conference gave birth to a variety of new ideas and research projects such as the use of a colposcopy-like instrument to detect early malignancies in otolaryngology or the use of Proteomics for the diagnosis in endoscopical operations. **It seems that the interdisciplinary concept of the NESA proved to be fruitful, as surgeons from different disciplines could profit from new ideas and techniques developed in other professions.**

Prize for the best presentation

As there were many excellent lectures, it was difficult to attribute the prize for the best presentation at the end of the conference. After many consultations, it was decided to divide the prize between three speakers for the originality and innovative character of their presentations:

- 1) **Kai Kuhnt** (Borna) for his lecture on “Resection of the neurovascular bundle as second step procedure in case of positive margins after nerve-sparing laparoscopic prostatectomy”
- 2) **Georg Slavka** (Vienna) for his presentation about “Laparoscopic hysterectomy - A computer-generated 3-dimensional animation of a surgical procedure”
- 3) **Soren Meisner** (Copenhagen) for his lecture about “Endoscopic placement of Self Expanding Metal Stents - first choice treatment of colo-rectal obstruction: Technique and results from a single center”

Invited speakers

Arie Admon
Dan Benhamou
Zion Ben-Rafael
Peter Biro
Christoph E. Broelsch
Gerhard Buess
Rabih Chaoui
Michelle Fynes
Claudio Giorlandino
Werner Grünberger
Liselotte Mettler
Parwis Mir-Salim
Farr Nezhat
Moshe Zvi Papa
Gralf Popken
Marc Possover
Arie Rosen
Klaus Schaarschmidt
Carsten Schmidt
Jörg Schmidt
Achim Schneider
Elizabeth A. Stewart
Albert Tuchmann
Klaus F. Wagner
Errico Zupi

International Scientific Committee

Zion Ben-Rafael
Peter Biro
Christoph E. Broelsch
Gerhard Buess
Rabih Chaoui
Gian Carlo Di Renzo
Jacques Donnez
Michelle Fynes
Werner Grünberger
Albert Huch
Oktay Kadayıfçı
Liselotte Mettler
Nor Ashikin Mokhtar
Farr Nezhat
Kypros Nikolaidis
Marc Possover
Rudolf Roka
Arie Rosen
Herbert Stark
Errico Zupi

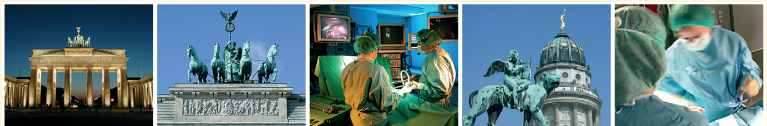

NESA Days 2006

An Interdisciplinary Endoscopical Conference

January 19-21, 2006

Hilton Hotel Berlin



NESA Days 2006

An Interdisciplinary Endoscopical Conference

January 19-21, 2006
Hilton Hotel Berlin

www.nesa-days.com

Welcome of the NESAs Days 2006	7
International scientific committee	12
Scientific programme	13
Invited speakers	25
Abstracts of the invited speakers	27
Useful information.....	65




NESA was founded in October 2004 as an initiative of surgeons from different disciplines who wanted to build an international interdisciplinary network of experts. The idea was to bring together authoritative professionals, with their knowledge and their scientific and practical experience, in order to simplify, standardize and optimize surgical procedures for the benefit of our patients.

The evaluation and the scientific projects of NESA focus on five disciplines: general surgery, obstetrics and gynaecology, urology, otolaryngology and anaesthesiology. NESA now – 14 months after its creation - includes members, departments, hospitals and international organisations in 27 countries. We are proud that during the NESA Days 2006 experts of notable international reputation will present a wide variety of re-evaluated and optimized surgical endoscopic procedures, along with new developments in basic sciences. The NESA Days will provide the opportunity for surgeons from different disciplines and countries to update their knowledge in their own profession and to be exposed to new ideas and techniques in other disciplines.

Following the basic idea of NESA, I expect that the interdisciplinary exchange and sharing of knowledge will stimulate new thinking and new ideas – for the benefit of the patients. You will find a highly professional platform to discuss new ideas and to broaden your knowledge in current surgical procedures as well as new developments. I encourage you to be active during the congress, challenging your colleagues and the speakers. And I am sure you will find a cultural program which gives you excellent opportunities to enjoy your friends and to acquire new ones.

I hope we will see you all again in the NESA Days 2007.

*Dr. Francesco De Meo
Director, The New European Surgical Academy*



Dear colleagues:

On behalf of the New European Surgical Academy (NESA), I would like to welcome you to our first international conference.

NESA was founded in 2004 in order to introduce and optimize surgical procedures and to spread surgical know-how to countries with minimal resources. One of the main questions we face is how to adhere to a humanistic approach and the principles of minimalism in an era of evidence-based medicine and high technical development.

The NESA Days present a unique opportunity to exchange experience and knowledge with specialists from different disciplines. The NESA Days 2006 is the first of a series of interdisciplinary conferences that are going to take place each year in a different country. During the NESA Days 2006, you will have the opportunity to meet internationally renowned experts and learn their way of thinking. With participants from more than 20 countries, we can look forward to establishing international professional connections with general surgeons, gynaecologists, otolaryngologists, urologists and anaesthesiologists.

I wish all of you a fruitful conference and hope that many of you will remain in contact with us and participate in our multinational surgical studies.

A handwritten signature in black ink, appearing to read "Michael Stark". The signature is fluid and cursive, with a long horizontal stroke at the end.

*Michael Stark MD
President, The New European Surgical Academy*



The Danish Surgical Society joined the NESAs in 2005. We appreciate the collaboration and think it will give rise to many fruitful discussions and, hopefully, common scientific projects. We find NESAs ideas concerning the re-evaluation of surgical procedures in order to optimize, simplify and standardize procedures very important. The present NESAs Days 2006 will hopefully be a significant step towards this goal.

The NESAs Days 2006 will be an excellent possibility for interdisciplinary exchange and sharing knowledge in different surgical areas as well as anaesthesiology. The very important topic of education and how to achieve practical skills in all the different specialities are another important focus.

The program contains presentations of many new surgical methods in general surgery and gynaecology along with the connection to modern anaesthesia, specifically addressing the increasing use of minimal invasive techniques in all kind of surgery.

We hope that this first NESAs meeting will serve as an appetizer for all European doctors treating patients with disorders requiring some kind of surgical intervention. We hope it will establish a basis for interdisciplinary discussions with the purpose of creating scientific studies that aim to optimize, simplify and standardize the different treatment modalities, which is one of the important goals of the NESAs.

We hope that you will enjoy the meeting in Berlin.

*Svend Schulze, MD DMSc
President, The Danish Surgical Society*



Welcome to the NESAs Days 2006

It gives me a great deal of pleasure to welcome you to this meeting, personally and on behalf of the New European Surgical Academy.

As surgeons we are all interested to refine and streamline surgical techniques in order to better serve to our patients. To paraphrase Victor Gomel, surgery performed other than for trauma and reconstruction demonstrates the inability, indeed the failure, of medicine. Therefore, when we are obliged to resort to surgery we must, whenever possible, use minimal access and effective techniques that are streamlined, bloodless and cost-effective.

To achieve this aim, we have to be open-minded, curious and willing to learn from other surgeons in our own as well as other disciplines. Furthermore, we have to be our own critics by reviewing our cases, preferably through video, to note the unnecessary or wrong steps that we have made during the procedure. Football players do it; why should we not?

This is the first congress of NESAs. Please express your opinions freely, based on your experience and understanding. To make the congress more fruitful, I encourage you to be active, challenge the speakers and the experts and participate in the discussion. I also encourage you to participate in the social programs, enjoy your old friends and acquire new ones. Enjoy Berlin – explore its historic, cultural and artistic richness.

Thank you for your participation.

Oktay Kadayıfçı MD

Head, Ob/Gyn Department of the Çukurova University (Adana, Turkey); President, The Turkish Society of Feto-Maternal Medicine and Perinatology



We live in a time of regulated specialty training where operative skills are catalogued in addition to the necessary basic skills training. Impact factors seem more important than operative performance. Innovations become important only after year-long studies striving for evidence. It is unusual to question "established" procedures. Based on this caricatured background, it not only makes sense to move the focus toward the direct patient-work, it even proves necessary to do so, especially

in the operative genre.

How shall things proceed? Innovations or new standards? Return to the established ones or shift towards new spheres? I am excited to find out what new ideas the interdisciplinary meeting NESAs Days 2006 may bring to our profession.

Klaus Vetter

President, The German Society for Obstetrics and Gynaecology (DGGG)

International scientific committee of the NESA Days 2006

Zion Ben-Rafael	Israel
Peter Biro	Switzerland
Christoph E. Broelsch	Germany
Gerhard Buess	Germany
Rabih Chaoui	Germany
Gian Carlo Di Renzo	Italy
Jacques Donnez	Belgium
Michelle Fynes	United Kingdom
Werner Grünberger	Austria
Albert Huch	Switzerland
Oktay Kadayıfçı	Turkey
Liselotte Mettler	Germany
Nor Ashikin Mokhtar	Malaysia
Farr Nezhat	USA
Kypros Nikolaidis	United Kingdom
Marc Possover	Germany
Rudolf Roka	Austria
Arie Rosen	USA
Herbert Stark	Austria
Errico Zupi	Italy

Scientific programme of the NESA Days 2006

Thursday, January 19

20:00 Get-Together and registration

Friday, January 20

Room 1

08:30 Welcome address

PLENARY LECTURES

09:00-09.30 Past and present of gynecologic laparoscopy, focus on hysterectomies
Liselotte Mettler (Kiel)

09:30-10:00 Complications of laparoscopic surgery in gynecology
Farr Nezhat (New York)

10:00-10:30 Computer-aided surgical planning and procedures
Albert Schaeffer (Bickenbach)

10:30-11:00 The proteome and the MHC-peptidome of human cancer cells
Arie Admon (Haifa)

11:00-11:30 Coffee break

11:30-13:00 State-of-the-art lectures

The role of endoscopy today

Chairmen: F. Nezhat, Z. Ben-Rafael, M.Z. Papa

Urological laparoscopy (from cutting stones to minimal invasive procedures)
Gralf Popken (Berlin)

The combined laparoscopic and vaginal approach in gynaecological malignancies
A. Schneider, C. Köhler (Berlin)

Role of laparoscopy in ovarian carcinoma
Farr Nezhat (New York)

Endoscopic treatment of gastrointestinal malignancies
M. Venturero, M.Z. Papa (Tel Aviv)

Room 2

11:30-13:00

State-of-the-art lectures

New developments

Chairmen: O. Kadayıfçı, W. Gruenberger, R. Robel

Minimally invasive, new technique for the creation of a neovagina in patients with vaginal aplasia

René Wenzl (Vienna)

Creation of artificial vagina with an endoscopic procedure

Werner Gruenberger (Vienna)

Innovative concepts and procedures in pediatric endoscopic surgery

Klaus Schaarschmidt (Berlin)

The laparoscopic neuro-functional pelvic surgery

M. Possover (Cologne), V. Chiantera (Naples)

Room 3

11:30-13:00

Organisation and quality management

Chairmen: G.C. Di Renzo, T. Mansky, B. Stitz

The Fast Track concept in colon surgery

Albert Tuchmann (Vienna)

Economic aspects of endoscopic hernia repair in Helios-clinics

Kai Witzel (Huenfeld)

Cost benefits of gynecological laparoscopy

G.C. Di Renzo, A. Mattei, S. Gerli (Perugia/ Florence)

Improvement of in-hospital mortality and other outcome parameters by quality management based on administrative medical data

Thomas Mansky (Fulda)

Parallels between air flight and surgery

Carsten Schmidt (Lufthansa)

Take-Home message

Thomas Mansky / G.C. Di Renzo

13:00-14:00

Lunch

Room 1

14:00-16:00

State-of-the-art lectures

The future

Chairmen: A. Tuchmann, K. Wagner, O. Rink

Realities of robotics and practice of endo-scopic surgery on virtual and real patients

Liselotte Mettler (Kiel)

The transperitoneal lymphadenectomy

A. Schneider, C. Köhler (Berlin)

Anesthesia and the future operative environment for laparoscopic surgery

Klaus Wagner (Lübeck)

Focused ultrasound therapy: Uterine fibroids and beyond

Elizabeth A. Stewart (Boston)

Anesthesia for the „new“ patient having laparoscopic surgery: 5 years from now

Klaus Wagner (Lübeck)

Virtual reality in surgical education

Albert Schaeffer (Bickenbach)

Room 2

14:00-16:00

State-of-the-art lectures

Alternatives to traditional methods

Chairmen: V. Gomel, M.Z. Papa, K. Witzel

Cryomyolysis and laparoscopy

Errico Zupi (Rome)

Importance of wireless capsule endoscopy for targeted surgical intervention in small bowel diseases

H. Hönicke, C. Rink (Aue)

Virtual surgical treatment of malignancy - MR guided focused ultraso

M.Z. Papa, Y. Inbar, A. Velaneu, S. Ayalon, D. Barsuck, M. Sareli, A. Yosipovich, Y. Kupilovich, A. Perl, B. Kaufman, R. Catane, D. Kopelman, A. Hannenel (Tel Aviv)

Preliminary experience with treatment of bone and liver tumors with MR guided focused ultrasound

Jens Ricke (Berlin)

Laparoscopic hysterectomy - A computer-generated 3-dimensional animation of a surgical procedure

G. Slavka, R. Wenzl (Vienna)

Anaesthesia for laparoscopic procedures

Peter Biro (Zurich)

Room 3

14:00-16:00

The use of endoscopy in gynecology

Chairmen: O. Kadayıfçı, E. Zupi, N. Samtaney

Laparoscopic assisted vaginal hysterectomy (LAVH) - A unique method to avoid unnecessary abdominal hysterectomies

Ralf Robel (Borna)

Comparison of laparoscopic and open hysterectomy

B. Stitz, C. Koch, A. Gaußmann, E. Schlothauer, U.B. Hoyme

Hysteroscopic endometrial resection versus laparoscopic supracervical hysterectomy for menorrhagia:

A prospective randomized trial

Errico Zupi (Rome)

Laparoscopic diagnosis of chlamydial salpingitis

U.B. Hoyme, U. Mahnert, A. Kentner (Erfurt)

Laparoscopic follow-up of uterine scar and post-cesarean adhesion with and without open peritoneum

A. Malvasi, A. Tinelli, R. Tinelli, G. Vittori, P. Scollo, O. Piccinni, C. Cavallotti (Bari)

Laparoscopic approach to dermoid cysts: combined surgical technique and ultrasonographic evaluation of residual functioning ovarian tissue

Errico Zupi (Rome)

A leap toward the top of the learning curve in gynaecologic endoscopy and episiotomy repair

A.J. Schneider (Rotterdam)

Take-Home message

E. Zupi / R. Robel / U.B. Hoyme

16:00-16:30

Coffee break

Room 1

16:30-19:00

The use of laparoscopy in malignancies

Chairmen: A. Schneider, W. Gruenberger, T. Benhidjeb

Laparoscopic radical nephrectomy in renal cell cancer -

Technique and oncological follow up in 170 cases

A.H. Wille, M. Tüllmann, J. Roigas, S. Deger,

S.A. Loening (Berlin)

Onward progress in colorectal cancer by

laparoscopic surgery

T. Benhidjeb, S. Anders, E. Bärlehner, M.W. Strik (Berlin)

The laparoscopic treatment of colorectal cancer

Albert Tuchmann (Vienna)

Laparoscopic retroperitoneal lymphadenectomy -

A routine diagnostic or staging modality in the

management of stage I nonseminomatous testis cancer

A.H. Wille, S. Deger, J. Roigas, S.A. Loening (Berlin)

Ductoscopy and ductoscopic biopsy: New perspectives

for early diagnosis and minimal invasive treatment of

breast cancer

M. Hünerbein, M. Raubach, B. Gebauer, W. Schneider,

P.M. Schlag (Berlin)

Laparoscopic staging of cervical cancer

M. Possover (Cologne), V. Chiantera (Naples)

Laparoscopic management of endometrial cancer

Farr Nezhat (New York)

Room 2

16:30-19:00

Modification of techniques in use

Chairmen: S. Schulze, G. Zografos, S. Meisner

Stress incontinence - New ideas

Michelle Fynes (London)

Endoscopic placement of Self Expanding Metal Stents -

First choice treatment of colo-rectal obstruction:

Technique and results from a single center

S. Meisner, C.A. Bertelsen (Copenhagen)

Non palpable mammographic solid tumors of the

breast: The mammotome biopsy

G. Zografos, F. Zagouri, G. Filipakis, D. Kouloxeri,

M. Tsakiri, G. Giannakopoulou, M. Kotsani, N. Pararas,

A. Noni, J. Bramis (Athens)

Management of scarring in endoscopic surgery

Arie Rosen (New Jersey)

Video-assisted airway management

Peter Biro (Zurich)

Nerve sparing, total mesometrial resection of

cervical cancer

Werner Mendling (Berlin)

Combined laparoscopic cholecystectomy and

myomectomy at the same patient. A case report

D. Stojanovic, D. Antic, B. Dakovic, M. Stojanovic,

Dj. Lalošević, P. Stevanovic (Belgrade)

Room 3

16:30-17:00

Prevention of complications in operative laparoscopy

Victor Gomel (Vancouver)

17:00-17:15

Extraperitoneal endoscopic repair of inguinal hernias

Kai Witzel (Huenfeld)

17:15-17:30

An alternative to laparoscopically assisted vaginal

hysterectomy

Michael Stark (Berlin)

17:30-19:00 **Round table: From surgery to minimal invasive and non-invasive procedures**
Z. Ben-Rafael (Tel Aviv), M.Z. Papa (Tel Aviv), G. Popken (Berlin), Elizabeth A. Stewart (Boston), G. Buess (Tuebingen), M. Stark (Berlin), D. Maor (Tirat Carmel)

20:30 **Cultural event: The Comedian Harmonists/ Dinner**

Saturday, January 21

Room 1

08:30-11:00

Advances in technology
Chairmen: G. Buess, R. Chaoui, M. Iaccarino

Technology and results with the radius surgical system, a suturing device with all degrees of freedom
Gerhard Buess (Tuebingen)

The 3-dimensional „Insect Eye“ laparoscopic Imaging system - Evaluation of a novel technology by a prospective randomized study
Y. Kaufman, A. Sharon, O. Klein, D. Spiegel, R. Auslander, A. Lissak (Haifa)

Teaching for endoscopic surgery, using the Tuebingen's Trainer
Gerhard Buess (Tuebingen)

Clinical ultrasonography: A decisive tool in gastroenterology and in abdominal surgery
Lucas Greiner (Wuppertal)

Intrauterine procedures guided by ultrasound
Rabih Chaoui (Berlin)

Computer controlled multifunctional robot
S. Devadurai, J. Maria Alen Dione Biju, S.P. Sathappan (Chennai)

Take-Home message
G. Buess / R. Chaoui / A. Schaeffer

Room 2

08:30-11:00

The role of endoscopy in urological surgery

Chairmen: G. Popken, D. Schulz, S. Jeffery

The past and future of endo-urology

Graff Popken (Berlin)

Results of the endoscopic correction of the vesico-ureteral reflux with consideration of complicated developments

U. Friedrich, R. Vetter, K. Eichhorn, S. Feilmeier (Erfurt)

Laparoscopic drainage of lymphoceles following kidney transplantation – Easy, safe and gentle

A. Paul, J. Treckmann, C.E. Broelsch (Essen)

Resection of the neurovascular bundle as second step procedure in case of positive margins after nerve-sparing laparoscopic prostatectomy

K. Kuhnt, D. Schulz, (Borna)

Laparoscopic partial nephrectomy in renal cell cancer - Results and reproducibility by different surgeons in a high volume laparoscopic center

A.H. Wille, M. Tüllmann, J. Roigas, S. Deger, S.A. Loening (Berlin)

Take-Home message

G. Popken / D. Schulz

11:00-11:30

Coffee break

Room 1

11:30-13:00

Endoscopy in otolaryngology

Chairmen: T. Wilhelm, P. Mir-Salim, M. Harell

Endoscopic nasal sinus surgery: An overview

Parwis Mir-Salim (Berlin)

Diagnostic progress or false evidence by in-vivo contact endoscopy - A critical point of view

Thomas Wilhelm (Borna)

Comparing endoscopic and open surgery in ENT
Herbert Stark (Vienna)

Endoscopic treatment of Hypopharyngeal- Zenker
dicaverticulum

Arie Rosen (New Jersey)

Endoscopic surgery of the larynx

Parwis Mir-Salim (Berlin)

Take-Home message

P. Mir-Salim / A. Rosen / M. Harell

Room 2

11:30-13:00

The role of endoscopy in gastroenterology

Chairmen: G. Buess, D. Amroch

Clipless laparoscopic cholecystectomy

D. Amroch, G. Fanti, G.B. Chiara (Pordenone)

Gastric volvulus - Laparoscopic gastropexy

A. Rammohan, P. Balaji, S. Floret (Chennai)

Transanal Endoscopic Microsurgery (TEM), technologies
and results of endoluminal surgery

Gerhard Buess (Tuebingen)

Laparoscopic cholecystectomy and its hazards

D. Amroch, G. Fanti, G.B. Chiara (Pordenone)

Anesthesia for gastrointestinal endoscopy in 2006

Dan Benhamou (Paris)

Take-Home message

G. Buess / D. Amroch

13:00-14:00

Lunch

Room 1

14:00-16:00

Workshop:

The multimodal postoperative analgesia and recovery

Peter Biro (Zurich), *Dan Benhamou (Paris)*,

Jochen Strauß (Berlin)

Room 2

14:00-16:00

Creative thinking

Chairmen: J. Dudenhausen, O. Kadayıfçı

Genetics and fibroids: The future is now

Elizabeth A. Stewart (Boston)

**Minimal invasive treatment of thoracolumbal
burst fractures**

J. Schmidt, U. J. Teßmann (Berlin)

**Endoscopic measuring of luminal dimensions in
case of airway stenosis**

Andreas Mueller (Gera)

**Arthroscopic assisted treatment of
intraarticular fractures**

Uwe-Jens Teßmann (Berlin)

**Avoiding the postnatal surgery by prenatal treatment of
fetal ovarian cysts**

Claudio Giorlandino (Rome)

Mammary ductoscopy

G. Zografos, F. Zagouri, G. Fillipakis, N. Pararas,

B. Oikonomou, M. Fotou, E. Stefanadi, J. Bramis (Athens)

Minimal invasive treatment of the fractured orbita

Reinhard Bschorer (Schwerin)

16:00-16:30

Coffee break

Room 1
16:30-19:00

With and against the stream...

Chairmen: M. Fynes, U. B. Hoyme

From Dr Freud to Dr Viagra: A century of controversies in treating erectile dysfunction

Ronald Virag (Paris)

Incidence of positive margins and early postoperative potency outcomes in nerve-sparing extraperitoneal laparoscopic prostatectomy

K. Kuhnt, D. Schulz (Borna)

Monitoring progress of labour – Comparing the use of cervicometry to the traditional clinical evaluation

Dan Farine (Toronto)

Virtual Euro-Mediterranean hospital as a tool for e-health

Georgi Graschew (Berlin)

Cystoscopic intradetrusor dysport injections in patients with refractory overactive bladder

S. Jeffery, R. Morley, M. Fynes (London)

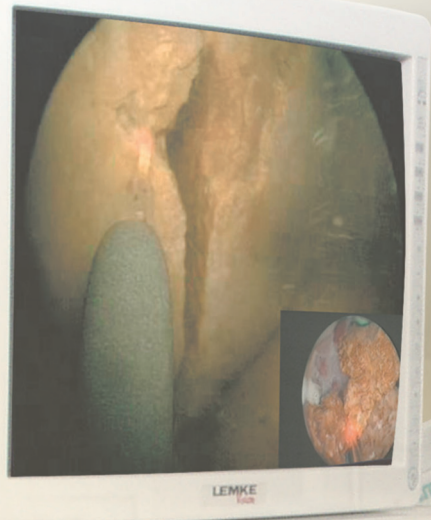
Optimizing living donor kidney transplantation - Donor procedure

A. Paul, J. Treckmann, C.E. Broelsch (Essen)

19:00

Final comments and price award for the best presentation

MINIMALE EINGRIFFE MIT ZUKUNFT



Seit 30 Jahren entwickeln und forschen wir im Sinne von Patienten und Ärzten. Unsere Produkte, Innovationen und Zukunftsprojekte haben die gemeinsamen Ziele:

- Sanftere Eingriffe und schnellere Heilung
- Leichter und sicherer Gebrauch der Geräte
- Kürzere Krankenhausaufenthalte
- Weniger Zeitaufwand und geringere Kosten für Ärzte und Kliniken

Wir freuen uns über Ihren Besuch auf unserem Stand auf der NESA 2006.

Mehr Informationen erhalten Sie unter www.WORLD-OF-MEDICINE.com



WORLD OF MEDICINE

Invited speakers

Arie Admon
Dan Benhamou
Zion Ben-Rafael
Peter Biro
Christoph E. Broelsch
Gerhard Buess
Rabih Chaoui
Michelle Fynes
Claudio Giorlandino
Werner Grünberger
Liselotte Mettler
Parwis Mir-Salim
Farr Nezhath
Moshe Zvi Papa
Graf Popken
Marc Possover
Arie Rosen
Klaus Schaarschmidt
Carsten Schmidt
Jörg Schmidt
Achim Schneider
Elizabeth A. Stewart
Albert Tuchmann
Klaus F. Wagner
Errico Zupi

In einem Meer von Kopien

Das Original



KS-18/D/06/04/A

STORZ
KARL STORZ – ENDOSKOPE

THE DIAMOND STANDARD

KARL STORZ GmbH & Co. KG, Mittelstraße 8, D-78532 Tuttlingen/Deutschland, Telefon: +49/7461/708-0, Fax: + 49/7461/708-105,
E-Mail: info@karlstorz.de

KARL STORZ Endoskop Austria GmbH, Landstraßer-Hauptstraße 146/11/18, A-1030 Wien/Österreich, Tel.: +43/1/715 60470, Fax: +43/1/715 60479,
E-Mail: storz-austria@karlstorz.at

www.karlstorz.com

Abstracts of the invited speakers

THE PROTEOME AND THE MHC-PEPTIDOME OF HUMAN CANCER CELLS

Arie Admon, MD

Department of Biology, Technion-Israel Institute of Technology, Haifa, Israel

Proteomics technologies are being used in cancer research with three main objectives. The first involves development of novel early detection tools by comparing the protein repertoires of cancer cell lines, fresh tumors and serum of cancer patients to those of healthy controls. This comparative proteomics approach is hindered by the complexity of the studied samples and the variability within the population. Another approach is based on serological (or humoral) proteomics. This methodology is based on identifying the repertoires of proteins from cancer cells against which specific antibodies are present in the sera of cancer patient and not of controls. These antibodies can become useful cancer markers for construction of protein arrays for rapid screening and therefore early detection of cancer. The third approach is aimed at analyses of the MHC peptide repertoires of cancer cells for immunotherapeutics developments.

MHC peptides originate from the degradation of both normal and disease-related proteins expressed in cancer cells. Since the repertoire of MHC peptides mirrors the degradation patterns of the cellular proteins (the degradome) rather than the proteome of the cells, their large-scale analysis complements the proteomics data in supplying information about rapidly degrading proteins. Rapidly degrading proteins include both defective ribosome products (DRiPs) and short lived proteins (SLiPs), which can point to defective protein processing in cancer cells. First, the large-scale identification of cancer cell proteins with emphasis on small cell lung carcinoma (SCLC) will be described. Second, the analysis of the proteins against which serological (antibody) responses are detected in sera of cancer patients will be discussed. Finally, I will talk about the identification of large numbers of MHC peptides from human cancer cells whose peptides include some that are possibly derived from tumor antigens, DRiPs and SLiPs, and whose turnover kinetics were also determined.

The large-scale analysis of MHC peptides began with transfection of expression vectors encoding different alleles of soluble HLA molecules (sHLA-A2, B7 and Cw4) into human cultured cancer cells. The soluble (and secreted) HLA molecules were recovered from the cells' growth medium in

large amounts. The peptides and proteins were identified by tandem mass spectrometry (MS/MS) followed by clustering of their MS/MS data by a newly developed software tool (Pep-Miner). We compared repertoires of the MHC peptides (the MHC peptidome) with the proteomes of the same cells. While many MHC peptides originated from relatively abundant long lived cell proteins, others originated from proteins previously undetected by any of the proteomics approaches. Combining the proteomics and the MHC-peptidome data offers a new and interesting point of view into the possible defects of cancer cells.

ANESTHESIA FOR GASTROINTESTINAL ENDOSCOPY IN 2006

Dan Benhamou, MD

Department of Anaesthesia and Reanimation, Hôpital de Bicêtre, France

Gastrointestinal endoscopy (GIE) has become quantitatively one of the most important interventional procedures performed today and has significantly increased the workload of Anesthesia Departments within the last twenty years. As an example, in France, among the 8 million anesthetic procedures performed each year, 15% are performed for GIE and it is even more noticeable when it is reminded that this activity was almost non-existent twenty years ago (Clergue F et al, 1999). More than half of these procedures are colonoscopic and more than one third are gastroduodenoscopic procedures.

Anesthesia for these procedures follows well-defined pathways and most often deep sedation/light general anesthesia is used while patients are maintained in spontaneous ventilation. Hypoxemia is generally easily prevented by nasal administration of oxygen. Retrograde choledochopancreatography represents only less than 1/30 of all anesthetic procedures performed for GIE but it is a more complex and risky procedure. Because it is often a long procedure (> 45 min) and the patient is positioned in ventral or lateral decubitus position, tracheal intubation is required in most cases. Moreover, as radiographs are taken during the procedure, complete immobilization is required, explaining why the use of neuromuscular blocking agents is necessary.

Fortunately, the vast majority of GIE procedures are scheduled cases which limit the increased anesthetic risk associated with emergency procedures. Upper intestinal hemorrhage is almost the only situation for which GIE is performed in emergency situation and because it is usually a short procedure in hemodynamically instable patients, anesthetic drugs are not used and the procedure is performed in awake patients.

In France, a preanesthetic visit is mandatory for scheduled procedures for which anesthesia is required and should be performed several days before to ensure that optimisation of the patient's condition, if necessary, can be done and that production pressure does not reduce quality and increases the risks.

A large number of these procedures can be performed in ambulatory patients and this seems a logical choice as more than 50 % of them are classified ASA 1 and do not present with an increased risk. Description of organisational conditions required for safe and effective practice of ambulatory anesthesia is out of the scope of this abstract but is easy to find in most anesthesia textbooks or Journals (Bryson GL et al, 2004, Gupta A 2004).

Three main factors should be discussed as far as anesthesia for GIE is concerned.

1- Anesthetic drugs which are used differ depending on the anesthetic depth required.

a) Light sedation can be used by gastroenterologists (anesthesiologists not involved) for gastroscopy and midazolam (oral or IV) is generally preferred (Trevisani L et al, 2004).

b) General anesthesia (including tracheal intubation and use of neuromuscular blocking agents) is used for retrograde choledopancreatography, although in some institutions, conscious sedation is the rule (Mazzon et al, 2005).

c) In most cases and especially for colonoscopy, deep sedation/light general anesthesia using propofol is the main technique used (Heuss LT, 2004). In most patients, propofol is used alone as intra and postoperative pain is limited (i.e. opioids may not be used [Moerman AT et al, 2004]) and several techniques of administration are being used: incremental top ups administered by the anesthesiologist as a response to patient movement reflecting pain, total intravenous anesthesia (TIVA) or target-controlled anesthesia while some centers advocate patient-controlled propofol anesthesia and claim that it works well (Bright E et al, 2003).

2- Hypoxemia is a constant risk associated with any type of anesthesia because of anesthetic drug-induced respiratory depression. Gastroduodenoscopic and other upper intestinal procedures which require introduction of the tube through the mouth increase the risk significantly because of local anesthesia (Ristikankare M et al, 2004) but also proportionally to the size of the endoscopic tube which reduces the airway calibre. This risk explains why pulse oximetry is mandatory during all these procedures. In the vast majority of cases, spontaneous ventilation is maintained and adequate oxygenation is provided through nasal administration of oxygen.

3- An unsolved and controversial problem is related to the respective role of the anesthesiologist, the gastroenterologist and the nurse-anesthetist in these procedures (Ulmer BJ et al, 2003, Motas D et al, 2004, Waring JP et al, 2003, Rex DK, 2004, Kulling D et al, 2003). In France, anesthesiologists (and in many units nurse-anesthetists) are involved and remain physically present during these procedures, thus ensuring a high level of safety. Gastroenterologists however, are not always convinced that anesthesiologists are necessary to ensure safety. The strong desire expressed by some gastroenterologists to manage themselves sedation for these procedures is reinforced by the shortage of anesthesiologists which exists in many European countries and might reduce expansion of the number of GIE procedures. The risk of severe complications and death still remains explaining why many experts still consider that the involvement of an anesthetist in airway management and the administration of intravenous sedation should be actively considered (Thompson AM et al, 2004).

Clergue F, Auroy Y, Pequignot F, Jouglu E, Lienhart A, Laxenaire MC. French survey of anesthesia in 1996. Anesthesiology. 1999 Nov;91(5):1509-20.

Bryson GL, Chung F, Finegan BA, Friedman Z, Miller DR, van Vlymen J, Cox RG, Crowe MJ, Fuller J, Henderson C; Canadian Ambulatory Anesthesia Research Education group. Patient selection in ambulatory anesthesia - an evidence-based review: part I. Can J Anaesth. 2004 Oct;51(8):768-81

Bryson GL, Chung F, Cox RG, Crowe MJ, Fuller J, Henderson C, Finegan BA, Friedman Z, Miller DR, van Vlymen J; Canadian Ambulatory Anesthesia Research Education group. Patient selection in ambulatory anesthesia - an evidence-based review: part II. Can J Anaesth. 2004 Oct;51(8):782-94.

Gupta A. Strategies for outpatient anaesthesia. Best Pract Res Clin Anaesthesiol. 2004 Dec;18(4):675-9

Bonta PI, Kok MF, Bergman JJ, Van den Brink GR, Lemkes JS, Tytgat GN, Fockens P. Conscious sedation for EUS of the esophagus and stomach: a double-blind, randomized, controlled trial comparing midazolam with placebo. Gastrointest Endosc. 2003 Jun;57(7):842-7.

Trevisani L, Sartori S, Gaudenzi P, Gilli G, Matarese G, Gullini S, Abbasciano V. Upper gastrointestinal endoscopy: are preparatory interventions or conscious sedation effective? A randomized trial. World J Gastroenterol. 2004 Nov 15;10(22):3313-7

Mazzon D, Germana B, Poole D, Celato M, Bernardi L, Calleri G, Fant F, Bernard M, Lecis P, Costan Biedo F; Societa Italiana di Anestesia, Analgesia, Rianimazione e Terapia Intensiva. Conscious sedation during endoscopic retrograde colangiopancreatography: implementation of SIED-SIAARTI-ANOTE guidelines in Belluno Hospital. *Minerva Anesthesiol.* 2005 Mar;71(3):101-9.

Heuss LT, Inauen W. The dawning of a new sedative: propofol in gastrointestinal endoscopy. *Digestion.* 2004;69(1):20-6.

Moerman AT, Struys MM, Vereecke HE, Herregods LL, De Vos MM, Mortier EP. Remifentanyl used to supplement propofol does not improve quality of sedation during spontaneous respiration. *J Clin Anesth.* 2004 Jun;16(4):237-43.

Bright E, Roseveare C, Dalglish D, Kimble J, Elliott J, Shepherd H. Patient-controlled sedation for colonoscopy: a randomized trial comparing patient-controlled administration of propofol and alfentanil with physician-administered midazolam and pethidine. *Endoscopy.* 2003 Aug;35(8):683-7.

Ristikankare M, Hartikainen J, Heikkinen M, Julkunen R. Is routine sedation or topical pharyngeal anesthesia beneficial during upper endoscopy? *Gastrointest Endosc.* 2004 Nov;60(5):686-94.

Ulmer BJ, Hansen JJ, Overlay CA, Symms MR, Chadalawada V, Liangpunsakul S, Strahl E, Mendel AM, Rex DK. Propofol versus midazolam/fentanyl for outpatient colonoscopy: administration by nurses supervised by endoscopists. *Clin Gastroenterol Hepatol.* 2003 Nov;1(6):425-32.

Motas D, McDermott NB, VanSickle T, Friesen RH. Depth of consciousness and deep sedation attained in children as administered by nonanaesthesiologists in a children's hospital. *Paediatr Anaesth.* 2004 Mar;14(3):256-60.

Waring JP, Baron TH, Hirota WK, Goldstein JL, Jacobson BC, Leighton JA, Mallery JS, Faigel DO; American Society for Gastrointestinal Endoscopy, Standards of Practice Committee. Guidelines for conscious sedation and monitoring during gastrointestinal endoscopy. *Gastrointest Endosc.* 2003 Sep;58(3):317-22.

Rex DK. The science and politics of propofol. *Am J Gastroenterol.* 2004 Nov;99(11):2080-3

Kulling D, Rothenbuhler R, Inauen W. Safety of nonanesthetist sedation with propofol for outpatient colonoscopy and esophagogastroduodenoscopy. Endoscopy. 2003 Aug;35(8):679-82.

Thompson AM, Wright DJ, Murray W, Ritchie GL, Burton HD, Stonebridge PA. Analysis of 153 deaths after upper gastrointestinal endoscopy: room for improvement? Surg Endosc. 2004 Jan;18(1):22-5

VIDEO-ASSISTED AIRWAY MANAGEMENT

Peter Biro, PD Dr. med

Department of Anaesthesiology, University Hospital Zurich, Switzerland

In about 3% of all intubation attempts, a sufficiently good view of the glottis cannot be achieved by means of direct laryngoscopy. A careful preanaesthetic interview, search of previous anaesthesia records and a thorough examination of the head-neck region can reveal up to 90% of possible major airway difficulties. However, there remain 10% of unpredictable difficult airway situations. The widely accepted gold standard technique, which is the elective awake fiberoptic intubation, can be applied under optimal conditions and without pressure of time. The unpredicted difficult airway is characterised by lack of the right equipment and expertise on the right spot at the right time. Therefore, easy to handle and efficient means for provisory securing the airway and in particular for maintenance of oxygenation are required. Video assisted airway management comprises video assisted laryngoscopy and video assisted intubation. In both cases, regular intubation equipment is expanded by an effective visualisation device that does not interfere with the familiar handling of the basic technique, but additionally offers an endoscopic view of the intubation pathway. The output of the visual signal is a bed side device containing a flat screen monitor. The interfaces between the immediate laryngoscopic equipment and the monitor is a small size unit containing an ultra long and narrow flexible fiberoptic, a light source and a CCD camera. In order to perform video assisted intubation, one must insert the long fiberoptic into the endotracheal tube, just like a conventional malleable guide wire. For this purpose, the fiberoptic is enforced with a wire for 30 cm of its distal end. Thus it can be manually bended by the user, as he considers necessary. Video assisted laryngoscopy is performed with a long fiberoptic inserted into the handle of a specially prepared laryngoscope. The tip of the fiberoptic replaces the electric bulb near the end of the spatula. Thus the light brought in by the fiberoptic provides for the necessary illumination and the view from the spatula is transmitted to the video camera respectively to the monitor

screen. The big advantage with these techniques is that the user must not familiarise himself to any alternative method. The intubation procedure remains as usual, but one is able to view simultaneously the image generated at the tip of the endotracheal tube. In the unpredicted difficult airway, video assisted devices are by far easier to handle, since they require no substantial modification of the familiar procedures. Thus, their application has a lower psychological threshold. The device is fast assembled, easy to clean and to sterilize. However, video assisted devices are not suitable for awake application, the stylet cannot be steered from a proximal port, are only suitable for oro-tracheal intubation and the fiberoptic has no suction or working channel. In conclusion, the video assisted intubation and laryngoscopy equipment is not intended to replace the flexible fiberoptic in the elective difficult airway management, which is still undisputedly the „gold standard“, but they are good substitutes for the flexible fiberoptic in the unexpected, anaesthetised difficult airway. If indicated, this equipment may be more convenient than the flexible fiberoptic because of easy teaching, easy learning, simpler handling, and better availability.

ANAESTHESIA FOR LAPAROSCOPIC PROCEDURES

Peter Biro, PD Dr. med

Department of Anaesthesiology, University Hospital Zurich, Switzerland

Laparoscopic surgery supersedes more and more the open surgical access to the abdominal cavity. Various advantages have been attributed to it, such as better cosmetic results, less postoperative pain and complications, better comfort and faster recovery, thus finally leading to a shorter in-hospital stay. Concerning anesthesia we must admit that side effects of pneumoperitoneum (PP) interfere with vital functions, in particular with respiration and hemodynamics. The insufflated gas elevates intraabdominal pressure (IAP) and displaces the diaphragm to cranial. IAP is transmitted to the thoracic cavity, and this causes rising airway pressure and decreasing total respiratory compliance. However, even though the PP has negative effects on respiration during the operation, in the postoperative period, strong benefits have to be considered. Patients undergoing open cholecystectomy as compared with laparoscopic access have shown by far more impaired lung function parameters, such as forced expiratory volume in the first second (FEV1) (decrease of 55 vs. 30%), time duration till the recovery of the affected FEV1 to baseline (9.5 vs. 5 days), peak expiratory flow on the second postoperative day (50 vs. 25%) and the frequency of postoperative atelectasis (90 vs. 40%). Only the functional residual capacity reduction on the first postoperative day was more expli-

cit in patients with laparoscopy (20 vs. 34%). There are additional effects caused by reabsorption of carbon dioxide (CO₂) leading to hypercarbia and acidosis. If the patient is breathing spontaneously, a rising PaCO₂ directly leads to increase the alveolar ventilation as a first line countermeasure, followed by enhanced renal secretion of acidic compounds and reabsorption of bicarbonate. However, in most cases controlled ventilation is applied, and the anesthetist has to adapt ventilation patterns in order to maintain normocapnia (which may not always be achieved completely). In pregnant women undergoing non-obstetric surgery, PP exerts negative effects on uterine blood flow and oxygen supply for the fetus. However, consequences affecting the anesthesiological approach have to be evaluated on an individual scale. Eventually, an open surgical procedure in neutral horizontal position should be considered. Cholecystectomy is the most often performed non-obstetric surgical intervention in pregnancy. Meanwhile 50% of cases are performed in laparoscopic mode. However, surgery before the 20th week of gestation bears a slightly elevated risk for preterm birth. Beside this, there is no further evidence for any difference in malformation frequency in open vs. laparoscopic surgery. Generally spoken, one cannot state a contraindication for laparoscopic surgery in pregnancy as a matter of principle. In the morbid obese patient, a markedly higher rate of complications and the necessity of a longer in-hospital stay has to be expected. However, as compared to open surgery, laparoscopic procedures present less problems with wound healing, and show a lower tendency for burst abdomen. These patients, in particular benefit from an early mobilization and early discharge from the hospital. Laparoscopic surgery and the applied anesthetic procedures are not free of complications and undesired side effects such as, aspiration of gastric content, inadvertent secondary unilateral bronchial endotracheal tube displacement, carbon monoxide poisoning, surgical emphysema, bleeding, pneumothorax and pneumomediastinum.

LAPAROSCOPIC DRAINAGE OF LYMPHOCELES FOLLOWING KIDNEY TRANSPLANTATION - EASY, SAFE AND GENTLE

Paul A, Treckmann J, Broelsch CE

Department of General, Visceral and Transplantation Surgery, University Hospital Essen, Germany

A lymphocele following kidney transplantation can congest the urinary outflow of the kidney. A symptomatic lymphocele occurs with an incidence of 5% after kidney transplantation.

Traditionally, post transplant lymphoceles are drained by widely opening the wall connecting the intraperitoneal cavity to the lymphocele cavity. This procedure implicates a re-exploration of the wound with potential problem of wound healing in immunocompromized patients.

Laparoscopy allows to fenestrate the lymphocele into the abdominal cavity with a minimal intraoperative trauma. The procedure is easy, fast and in most cases without inconvenience for the patients. The application of the endoscopic ultrasound allows to perform laparoscopic fenestration also in most of the patients with unfavourable locations of the lymphocele like lower pole of the kidney beside the ureter and the vessels.

OPTIMIZING LIVING DONOR KIDNEY TRANSPLANTATION - DONOR PROCEDURE

Paul A, Treckmann J, Broelsch CE

Department of General, Visceral and Transplantation Surgery, University Hospital Essen, Germany

Living donor kidney transplantation has been successfully performed since 50 years in an open/ conventional technique. The ideal donor procedure should barely show complications, should be little bothering and should have no long time morbidity. For the open procedure different accesses were developed: laparotomy with median, paramedian, transverse incisions and retroperitoneal accesses with subcostal, pararectal and flank incisions.

The first laparoscopic donor procedure was performed in 1995 by Ratner. For these procedures, different modes of handling method immanent problems appear in the literature like complete laparoscopic, hand assisted and roboter assisted operations.

Laparoscopic procedures seem to reduce operative trauma resulting in earlier recovery, less pain, less fatigue and less wound related morbidity. Nevertheless, high quality controlled trials comparing laparoscopic procedures with the „best“ conventional method do not exist.

Laparoscopic donor nephrectomies have at least a longer learning curve than open procedures making it difficult to recommend this operation for low volume centres.

Competing the potential advantages of laparoscopic procedures, the processes in conventional donor operations were optimized with modern perioperative anesthesiologic and pain management and other components of „fast track“ rehabilitation in surgery.

The results of more than 150 living donor operations with different techniques will be presented.

THE PRENATAL TREATMENT OF FETAL OVARIAN CYSTS AVOID THE POSTNATAL SURGERY

Giorlandino C, Bagolan P**, Nahom A**, Coco C*, Mobili L*, Brizzi C*, Mangiafico L*, Spanò G*, Aleandri V***

***Artemisia Medical Group, Department of Maternal Fetal medicine, Rome, Italy*

*** Ospedale Babin Gesu, Rome, Italy*

PURPOSE:

To evaluate if the prenatal aspiration of the ovarian cyst improves the outcome and avoids the traumatic postnatal surgery, a statistical analysis to calculate the cut-off for the size of the lesion was performed. The authors evaluated the outcome of simple fetal ovarian cysts after prenatal aspiration and considered criteria for this procedure.

BACKGROUND:

The Ovarian torsion causing the loss of an ovary represents the most common complication of fetal ovarian cysts. However, criteria for prenatal decompression still need to be evaluated. Previous experience of the authors showed that large simple cysts have a poor outcome, whereas preliminary attempts of their „in utero“ aspiration were all successful and uneventful.

METHODS:

This prospective study includes 109 ovarian cysts (82 simple, 42 showing torsion) diagnosed in 122 fetuses from June 1992 to June 2005, and followed up until spontaneous resolution or surgery. Prenatal aspiration was performed in the case of simple cysts ≥ 5 cm in diameter.

The outcome of these cysts was compared with a series of similar cysts not aspirated in the authors' previous study. The outcome of simple cysts less than 5 cm and cysts with a prenatal ultrasound appearance of torsion also was evaluated.

RESULTS:

Prenatal decompression was performed without any complications in 24 cases: 12

20 regressed subsequently; 2 showed torsion postnatally. This outcome is significantly better than that of similar cysts not aspirated in the authors' previous study.

Among the 58 simple cysts less than 5 cm, 44 resolved spontaneously; 14 had complications, 12 of which showing torsion. Among the 58 cysts showing torsion 24 required oophorectomy; 15 spontaneously disappeared at ultrasound, one of which required surgery for intestinal obstruction secondary to adhesion of a necrotic ovary; one patient was lost of the follow-up.

CONCLUSIONS:

Prenatal aspiration of ovarian cysts appears effective and safe: a „cutoff“ of 4 cm is to recommend. Cysts with ultrasound pattern of torsion persisting postnatally require surgery; options for their management, when sonographically disappearing and asymptomatic, need to be investigated.

CREATION OF ARTIFICIAL VAGINA - AN ENDOSCOPICAL PROCEDURE

Werner Grünberger, MD

Semmelweis-Klinik, Vienna, Austria

Mayer-Rokitansky-Kuester-Hauser-Syndrom is a very rare congenital malformation with an incidence rate of only one in 10 000 newborns. This means that in Austria there are 8 and in Germany 80 girls born each year with this condition. More than 30 different methods to correct this malformation are described in the literature. In the Seventies Prof. Vecchietti invented a simple procedure, where the skin of the perineum is pulled between bladder and rectum, to create an artificial vagina.

Since 1979 I have been very successful with this procedure and have modified it to an endoscopic approach. As of now I have treated 244 cases with patients coming from my native Austria and many foreign countries. With the use of some newly invented instruments and numerous surgical improvements I achieved a near zero morbidity. Cosmetic and functional results are perfect.

The procedure will be shown in a videotape.

PAST AND PRESENT OF GYNECOLOGIC LAPAROSCOPY, FOCUS ON HYSTERECTOMIES

Liselotte Mettler, MD

Department of Obstetrics and Gynaecology, Campus Kiel, University Hospitals Schleswig-Holstein, Germany

Twenty years after the first description of vaginal hysterectomy with laparoscopic assistance by Kurt Semm in 1984 and 16 years after the publication of the so-called laparoscopic assisted vaginal hysterectomy (LAVH) by Harry Reich in 1989, it is about time to review and evaluate the real benefits of laparoscopic hysterectomy. Although laparoscopic surgery is well accepted by gynaecologists worldwide for the treatment of certain gynaecological conditions, laparoscopic hysterectomy in Germany, and probably worldwide, is still only performed by a few specialists. Highly skilled surgical techniques, longer operating time and expensive technology are suggested to be the deterring factors. Laparoscopic hysterectomy, in its different forms is an attractive and safe procedure for the management of benign gynaecological conditions and many authorities recommend its use on a larger extent. On the other hand in our opinion, the use of laparoscopic hysterectomy for oncological indications is still controversial. Extensive experience of over 15 years, in practising and teaching various forms of laparoscopic hysterectomy, namely, laparoscopically assisted vaginal hysterectomy (LAVH), total laparoscopic vaginal hysterectomy (TLVH), classic intrafascial supracervical hysterectomy (CISH) and laparoscopic supracervical hysterectomy (LSH) has led me to the firm conclusion that these techniques are advantageous to patients if performed for the appropriate indication. In particular, subtotal or supracervical hysterectomy, with the cervix remaining in its place, is associated with fewer complications and a very favourable outcome for the patient. Radical laparoscopic vaginal hysterectomy (RLVH), the last variant in our exposé, is only successful in an expert's hands. The surgical techniques of these varieties of laparoscopic hysterectomies will be described and illustrated in this lecture.

REALITIES OF ROBOTICS AND PRACTICE OF ENDOSCOPIC SURGERY ON VIRTUAL AND REAL PATIENTS

Liselotte Mettler, MD

Department of Obstetrics and Gynaecology, Campus Kiel, University Hospitals Schleswig-Holstein, Germany

To provide the virtual environment in a training system for laparoscopic surgery, a realistic 3-D representation of the anatomic situs is derived from

2-D medical image data using imaging algorithms and visualisation techniques. Thus, an intuitive handling of the instruments is guaranteed and the surgeon is able to perform endoscopic techniques on the virtual situs.

The endoscopic training system developed at the Karlsruhe Research Centre in co-operation with the Department of Obstetrics and Gynaecology, Campus Kiel is named "VSOne". The minor pelvis with the gynaecological organs can be simulated in a virtual environment. By means of realistic user interface the gynaecologist is able to grasp, coagulate, cut, introduce new instruments, suture, apply clips, initiate bleeding, stop bleeding and push aside the intestines, all in a realistic simulation scenario.

In addition to conventional laparoscopy and hysteroscopy training methods, it is now possible to offer doctors a virtual training system for minimally invasive surgery with a realistic user interface. Methods and tools for the realistic modelling of deformable objects and simulation of surgical interactions are to hand. A capability score can be drawn up for each trainee. Visual effects such as active deformable objects and particle systems for fluid simulation enhance the simulation realism.

Virtual Reality Simulation

Virtual reality based surgical simulation systems will become even more realistic in the future. They will be integrated into multimedia teaching and training environments and all surgical disciplines will be covered. Training on human cadavers is still an alternative but this is often more difficult than working on the virtual situs.

Robotic Camera Holding Arms

There are many different types of robotic camera holding systems. AESOP (Automated Endoscopic System for Optimal Positioning) with hand, foot or voice control, received the robot of the year award 2000 in medical application. The surgeon can direct the articulated metal arm by voice control. The laparoscope can be moved in any direction - left, right, up, down, forward or backward. In addition, laparoscopic views can be keyed in for return visits by using the memory feature which is available for three positions. AESOP allows the surgeon to use both his arms to control the instruments. It enables a tremor-free, voice-controlled movement of the camera.

The Zeus system uses three robots, one for camera movement and two for robotic instrumentation. In addition to the voice-controlled movement of the instruments, all data are registered. A number of companies offer intelligent operating room systems:

daVinci Surgical System

Using the daVinci Surgical System it is possible to operate with the look and feel of open surgery, performing complex surgical manoeuvres through 1 cm ports in a sitting position with a so-called Surgical Immersion technology. The eyes and hands of the surgeon are completely immersed in the patient. True-to-life, 3-D vision and instinctive operative control make complex MIS procedures feel like open surgery.

The surgical revolution initiated by the daVinci Surgical System enables surgery to be performed with unprecedented precision and control. The immersion in the patient by looking into the daVinci™ has so far only been practised in a few centres, mainly in heart and general surgery. Results on patients are minimal, but fascinating.

ENDOSCOPIC NASAL SINUS SURGERY: AN OVERVIEW

Parwis Mir-Salim, PD Dr. med

Klinikum im Friedrichshain, Berlin, Germany

Endoscopic sinus surgery is a procedure in which the surgeon examines the nasal cavity and the drainage ways of the paranasal sinuses. Using state of the art endoscopes and microsurgical instruments, abnormal and obstructive tissues are then removed. In most cases the surgery is performed endonasally, leaving no external scars. Mild discomfort and nasal secretion are common postoperatively .

Whereas, in the past, attention has often been directed towards the removal of all sinus mucosa from the major sinuses, the endoscopic approach relies on the principle that sinus disease is reversible if the underlying obstruction can be identified and corrected. A careful diagnostic workup is therefore important and consists of examination, CT scans of the sinuses, rhinomanometry, in special cases nasal cytology and smell testing. Surgery is usually recommended only after medical therapy has failed.

The advantage of endoscopic sinus surgery is the philosophical recognition that the surgical goal is to open the natural drainage channels, thereby restoring normal physiologic function. This differs greatly from past procedures, which were ablative and destructive. Other advantages over past sinus surgeries are: diminished post operative discomfort by application of resorbable nasal packings and decreased bleeding risk because of tissue sparing instruments. This contributes to a shorter recovering time and most importantly, a 80% success rate.

The different surgical steps of endoscopic sinonasal surgery are demonstrated. The anatomy has often a great variety. The ethmoid roof is part of the anterior skull base, the sphenoid sinus is located within the central skull base. Potential surgical complications include bleeding, orbital hematoma, swelling, endonasal synechia or infection. Rare complications are intracranial entry and cerebral injury. Using endoscopes and microscope major complications such as visual loss, CSF Leaks or Internal Carotid injury are fortunately rare.

Endoscopic sinus surgery is nowadays a well established procedure. In future Navigation systems and powered instruments will improve the outcome.

ENDOSCOPIC SURGERY OF THE LARYNX

Parwis Mir-Salim, PD Dr. med

Klinikum im Friedrichshain, Berlin, Germany

Endoscopic procedures of the larynx are well established for the treatment of benign laryngeal diseases since several decades. In cases of malignant larynx tumors total or open partial laryngectomies were common methods. These procedures require a tracheotomy and frequently lead to long term aspiration and hoarseness.

In the 80's the endoscopic transoral laserresection of laryngeal carcinomas was introduced. Further technical development has this method nowadays optimized within the therapy of laryngeal malignancies. The goal in conservation laryngeal surgery is to preserve maximum laryngeal function without compromising the cure rate. Compared to any other procedure this surgery maintains physiologic speech and swallow function without the need for a permanent tracheostoma.

Similar to the conventional surgery complete removal of all malignant disease should be achieved while preserving the 4 basic functions of the larynx: deglutition, respiration, phonation, and airway protection. Regardless of the specific conservation laryngeal procedure, a few key principles must be respected.

A diagnostic endoscopy enables the surgeon to assess tumor extension and exposition that determines eligibility for organ preservation surgery. Furthermore, it is vitally important to assess subglottic growth. At least the cricoarytenoid unit is the basic functional unit of the larynx. As long as

one unit can be preserved, the patient is a potential candidate for organ preservation laryngeal surgery.

The current literature is specified as a metaanalysis and proves the suitability of this method in the treatment of glottic and supraglottic Tis - T2 stages. The borders of the transoral lasersurgery of the larynx are pointed out on the basis newest studies. Several clinical examples were demonstrated.

COMPLICATIONS OF LAPAROSCOPIC SURGERY IN GYNECOLOGY

Farr Nezhat, MD FACOG

Division of Gynecologic Oncology, Mount Sinai Medical Center, New York, USA

Complications of laparoscopic surgery can be divided into two general categories. The first includes those complications, which are inherent to laparoscopy itself, regardless of the specific procedure being performed. These include complications such as subcutaneous emphysema or laceration of the abdominal wall and trocar injuries to inferior epigastric vessels, the bowel or major retroperitoneal vessels. The second group of complications includes those that are inherent to a specific procedure being performed.

In this review we use Laparoscopic lymphadenectomy as an example to discuss some of these complications.

Lymph node status is the most important prognostic factor in gynecologic cancer and surgical removal of pelvic and / or Para-aortic lymph nodes for histologic assessment, is an integral part of staging for gynecologic malignancies. Additionally, removal of the bulky lymph nodes may have therapeutic benefit.

Technically there are several benefits of laparoscopic approach to pelvic and Para-aortic lymphadenectomy. The laparoscope provides a 7-10 fold magnification of the operative field allowing identification of small tributary vessels. Further, the pneumoperitoneum facilitates the development of pelvic spaces and decreases venous oozing, thereby maintaining a clean operative dissection with good visualization of nodal bundles.

1- Vascular injuries- In a series of laparoscopic lymphadenectomy, seven out of nine vascular complications occurred as the result of trocar injury

to the anterior abdominal wall vasculature. Potential vascular compromise specific to pelvic lymphadenectomy includes injury to the obturator, internal iliac, external iliac, or the common iliac vessels. Vessels at risk for injury during Para-aortic lymphadenectomy include the aorta and vena cava, as well as the common iliac, inferior mesenteric, lumbar, ovarian, and renal vessels.

2- Genitourinary injuries- Cystotomy during trocar insertion, adhesiolysis or dissection with Endoscopic scissors with or without electrocautery has been described as a complication of laparoscopic lymphadenectomy, although not specific to this procedure. Pelvic lymphadenectomy places the ureter at risk for sharp, crush or thermal injury. The lumbar portion of the ureter is at risk during Para-aortic lymphadenectomy.

3- Abdominal wall metastases and peritoneal tumor dissemination- Abdominal wall metastases, also called port or wound site metastases, have been reported after both laparoscopy and laparotomy. The incidence of these complications has been 1% after laparotomy and 1-3% after laparoscopy. Port sites are contaminated during tumor extraction or withdrawal of contaminated ports. The risk of contamination is higher if abdominal insufflation is lost during tumor extraction or port withdrawal. To prevent this complication, removal of all specimens using an endobag, removal of all ports while the abdomen is still insufflated and immediate local treatment of the contaminated ports with a cytotoxic agent, is mandatory.

4- Complications requiring laparotomy- Complications resulting in laparotomy have been related to damage to the ureter, bladder, bowel and vascular structures. The incidence of conversion to laparotomy in 449 cases from four large studies has been reported to be 9.3%.

LAPAROSCOPIC MANAGEMENT OF ENDOMETRIAL CANCER

Farr Nezhat, MD FACOG

Division of Gynecologic Oncology, Mount Sinai Medical Center, New York, USA

Endometrial cancer is the most common malignancy among women in the developed world, with an estimated 40,880 cases and 7,310,000 deaths in 2005. Currently, the standard treatment involving removal of uterus, tubes and ovaries and surgical staging is performed via laparotomy at most centers around the world.

Since its introduction in the early 1990s, laparoscopic surgery for the staging and treatment of endometrial cancer has become a widely accepted alternative to the traditional laparotomy. In the absence of large-scale randomized controlled trials to validate the benefits of laparoscopy over open surgery for the primary management of endometrial cancer, the feasibility and safety of the laparoscopic approach have been established from several cohort and case-control studies in the recent literature. The results of prospective series and small randomized trials comparing laparoscopy and open procedures in women with endometrial cancer showed that the laparoscopic management allows a reduction of perioperative complications and a faster recovery, with similar overall and disease-free survival.

ROLE OF LAPAROSCOPY IN OVARIAN CARCINOMA

Farr Nezhat, MD FACOG

Division of Gynecologic Oncology, Mount Sinai Medical Center, New York, USA

Approximately 80% of women who have ovarian cancer are discovered with advanced disease (stage III or IV), while the remaining patients present with stage I or II disease. Patients who appear to have disease limited to one ovary (stage Ia) require a full surgical staging procedure. This includes aspiration and cytologic assessment of all pelvic and abdominal fluid, pelvic and para-aortic lymph node sampling, infracolic omentectomy, and biopsies of the peritoneum from the cul-de-sacs, paracolic gutters, and diaphragms. One-third of the patients who appear to have disease confined to the ovary are upstaged after a surgical staging procedure. The incidence of positive lymph nodes is as high as 24% in stage I disease.³⁹ A national cooperative study found that 28% of patients thought to have stage I disease were upstaged after complete surgical staging. Inadequate staging can lead to improper postoperative therapy and a poorer prognosis.

The standard preoperative evaluation includes a history and physical, pelvic examination, a Papanicolaou smear, complete blood count, liver profile, and chest x-ray. Intravenous pyelography, barium enema, colonoscopy, and gastrointestinal series are utilized as indicated by the symptoms and physical exam. Ultrasound can be helpful in evaluating an adnexal mass for cystic and solid components, but the findings are not diagnostic of the malignancy of a mass.^{41,42} CT scans are helpful in preoperative planning for patients with an upper abdominal mass or liver metastasis in asymptomatic women and those with normal liver function tests.

The standard therapy for a histologically confirmed ovarian cancer is a cytoreductive operation to eliminate all gross disease. This procedure generally includes a total abdominal hysterectomy and bilateral salpingo-oophorectomy, an infracolic or total omentectomy, and pelvic and para-aortic lymph node sampling. Multiple retrospective studies have shown that survival is improved if patients have no residual lesions larger than 2 cm in diameter. Although no prospective studies randomizing patients to primary surgery or chemotherapy have been conducted, a trial of interval cytoreduction after three cycles of chemotherapy revealed a survival benefit for patients who had an optimal resection of their disease compared with patients who did not.

Laparoscopic Staging

The use of laparoscopy to surgically stage a patient with stage I or II ovarian cancer has been reported. Pomel and coworkers described 10 patients who underwent complete surgical staging for presumed stage I ovarian cancer. These procedures included peritoneal washings, peritoneal and ovarian biopsies, infracolic omentectomies, and pelvic and para-aortic lymphadenectomies. A median of six pelvic and eight para-aortic nodes from each homolateral chain was obtained. No intraoperative complications occurred. One patient had a postoperative pulmonary embolism, and another required laparotomy for hemoperitoneum secondary to bleeding from the vaginal cuff (two patients had laparoscopically assisted vaginal hysterectomies).

Second-Look Laparoscopy

Although the indication for second-look operations in patients with ovarian cancer after chemotherapy is debatable, laparoscopy can safely replace laparotomy in most cases. As many as 50% of patients with negative second-look procedures will have a recurrence. Improvements in laparoscopic equipment and skills increased the sensitivity and safety of second-look procedures.

VIRTUAL SURGICAL TREATMENT OF MALIGNANCY - MR GUIDED FOCUSED ULTRASOUND

*Papa MZ, Inbar Y, Velaneu A, Ayalon S, Barsuck D, Sareli M, Yosipovich A, Kupilovich Y, Perl A, Kaufman B, Catane R, Kopelman D, Hannenel A
Chaim Sheba Medical Center, Tel Hashomer & Tel Aviv University, Israel*

The use of high energy focused ultrasound waves (FUS) to destroy tumor tissue will be described. High energy FUS causes cell death by raising

the temperature of the treated tumor high enough to create cell protein denaturation, cell membrane damage and cell death. The tissue destruction is at the focus point of the ultrasound beams with extremely high heat gradients between the target cells and surrounding tissue, thus the effect of the FUS energy is concentrated at the target, leaving the healthy tissue safe. The combination of the FUS generator with the MR allows accurate planning of the treatment, real time imaging and heat measurements in the treated tissue.

Our experimental experience in humans and animal models using FUS in the breast, uterus, bone and liver will be described and the future potential of this type of tumor ablation and other types of tumor ablation will be discussed.

ENDOSCOPIC TREATMENT OF GASTROINTESTINAL MALIGNANCIES

Moris Venturero MD, Moshe Zvi Papa MD

Department of Surgery and Surgical Oncology, The Chaim Sheba Medical Center, Tel Hashomer, Israel

Minimally invasive, laparoscopically assisted surgery was first introduced in early 1990s for benign and malignant colorectal conditions. Acceptance of laparoscopy for the management of oncological disease has been slow due to the increased complexity of the technique, requirement of technological advances, and fears for the oncological safety of the approach. Like the laparoscopic approach for other operations, minimally invasive colectomy showed potential benefits of improved short-term outcomes. Special concerns have been raised; that laparoscopic approach may compromise survival by failing to achieve a proper oncologic resection or adequate staging, or by altering patterns of recurrence. Until recently, it was unclear whether minimally invasive surgery for colonic malignancies would achieve adequate oncologic resection. This review provides an overview of randomized controlled trials that report the short- and long-term outcomes after laparoscopic colectomy for cancer. The evidence against an adverse effect of laparoscopic surgery for colon cancer is strengthened.

THE PAST AND FUTURE OF ENDO-UROLOGY

Graf Popken, PD Dr. med

Department of Urology, HELIOS Klinikum Berlin-Buch, Berlin, Germany

In the preendoscopic era cutting stones was a common and dangerous operation connected with a high mortality. Since developing the cystoscope by Nitze (1879) endoscopic procedures in the urinary tract have been developed continuously.

Cutting stones in the urinary tract were performed in less than 1%. Most of those were treated by extracorporal shockwave lithotripsy and by endoscopic diagnostic and therapy in the lower and upper urinary tract. Hereby multimodal lithotripsy can be performed, it is less invasive and is connected with a low morbidity rate.

Just as benign and malignant alterations as superficial bladder cancer and benign prostate hyperplasia can be diagnosed and treated by endoscopic procedures assisted by photodynamic diagnostic and different types of laser.

The future of endourology is to minimize those instruments for diagnostic and therapeutic procedure to make handling for the urologist and the patient more comfortable and to minimize the trauma as well as to prevent those diseases.

UROLOGICAL LAPAROSCOPY (FROM CUTTING STONES TO MINIMAL INVASIVE PROCEDURES)

Graf Popken, PD Dr. med

Department of Urology, HELIOS Klinikum Berlin-Buch, Berlin, Germany

On September 23, 1901, Georg Kelling, a gastroenterologist and surgeon from Dresden, performed the first laparoscopic intervention with an Nitze cystoscope on a dog in Hamburg. Although his pioneering achievements have hardly been acknowledged, modern laparoscopy has confirmed Kelling's visions and scientific work in almost all aspects. In light of the enormous developments of the last decades concerning laparoscopy, the ideas of Georg Kelling seem to be visionary. The use of trocar, gas and light, which was described by him 100 years ago, is still valid. His statement for the use of celioscopy/laparoscopy with reduced trauma, fast reconvalescence and reduction of treatment cost are more up to date than ever before.

Since this time different surgical and urological endoscopic procedures have been described in the retroperitoneum, pelvis and abdomen:

- 1989.....Dubois.....Cholecystectomy
- 1991.....Schuesslerpelvic lymph node dissection
- 1991.....ClaymanNephrectomy
- 1998.....VallancienProstatectomy

Nowadays we have several simple and complex urological laparoscopic procedures from which some are first line therapy such as, for example, the adrenalectomy and the nephrectomy.

THE LAPAROSCOPIC NEURO-FUNCTIONAL PELVIC SURGERY

Marc Possover*, Vito Chiantera**

* *Department of Obstetrics and Gynecology, St. Elisabeth-Hospital, Cologne, Germany*

** *Department of Gynecology and Obstetrics, University of Naples, Italy*

We report the feasibility of the laparoscopic approach to all the pelvic somatic and autonomous nerves. Due to the magnification effect and the possibility of a blood free dissection even in the deepness of the pelvis, laparoscopic surgery in the retroperitoneum is becoming one of the most useful and important instrument for learning the pelvic retroperitoneal anatomy: Using the laparoscopic transperitoneal approach, an exposure of the sacral plexus, the sciatic nerve, the obturator nerve and the gluteal nerves as well as the pelvic splanchnic nerves was performed. Based of this new knowledge of pelvic neuroanatomy, we have developed the „nerve-sparing Laparoscopic Assisted Radical Vaginal Hysterectomy“ for therapy of patient with cervical carcinoma as well as the „laparoscopic assisted vaginal parasympathetic-nerve-sparing“ resection of the rectum with deep anterior colorectal anastomosis in extended endometriosis.

This new possibility of a minimal invasive surgical approach of all somatic and autonomous pelvic nerves combined by the LANN technique opened the field of new disciplines, the „laparoscopic neurofunctional pelvic surgery“: We have reported about our first experience of two indications for laparoscopic pelvic neurosurgery:

- the laparoscopic neurolyse of the sciatic nerve by endometriotic infiltration of the foramen ischiadicus
- the laparoscopic neurolysis of the pudendal nerve in situation of Alcock canal syndrom

The laparoscopic approach to the pelvic nerves may become widespread,

not only for sparing the nerves during radical pelvic surgery but also on the field of the FES.

LAPAROSCOPIC STAGING OF CERVICAL CANCER

Marc Possover, Vito Chiantera***

** Department of Obstetrics and Gynecology, St. Elisabeth-Hospital, Cologne, Germany*

*** Department of Gynecology and Obstetrics, University of Naples, Italy*

While a long learning time is required to master the laparoscopic radical lymphadenectomy and the radical vaginal hysterectomy technique, the use of laparoscopy for staging of cervical cancer should find large resonance and is easy and quick to learn. Only the histological assessment of the expansion of a tumour illness gives a reliable report related to prognosis. Lymph node status and tumor infiltration in pelvic tissue and the neighbouring viscera are the most important prognosis parameters in cervical cancer. These parameters can be endoscopically evaluated with good reliability so that the therapy can be better adapted to the tumor and the patient is more involved in the decision. The histological results of the posterior bladder biopsy, pelvic/para-aortal lymph nodes or suspicious intra-abdominal results help to make the decision whether surgery or radiochemotherapy is more useful. Furthermore, the extension of the operative procedure or the size of the radiation field can be individually adapted.

The laparoscopic staging with the laparoscopic lymph node staging should lead to a change in the staging of larger tumors. Computed tomography and Magnetic Resonance Imaging as an indirect method to prove lymph node metastasis have limited value of evidence. When the extent of organ infiltration of the bladder and the rectum/douglas is laparoscopically examined in comparison to the photodokumentation procedure, there is not enough sensitivity with the MRI. The laparoscopic evaluation of true tumour expansion in a series of 128 women with tumours >4cm in diameter lead to a change in the therapeutic approach by 22,6%. When a preoperative chemotherapy is planned a laparoscopic staging can also be recommended as the tissue changes caused by the chemotherapy or radiochemotherapy makes orientation based on the frozen-section examination on biopsies or lymph node tissue doubtful at the final operation.

In a laparoscopic histopathologic proven regional tumour expansion into the neighbouring viscera or to the peritoneum it is possible to stop the

operation and change to a primary radiochemotherapie without disturbing the blood supply of the tumour.

Such laparoscopic staging can be performed as a day-case. After receiving the histological results the further procedure can be planned directly with the patient and through the omitting of the laparotomy the radiotherapy or radiochemotherapy can beginn quickly without risking the side affects of radiation through extensive adhesions or wound healing disturbances.

MANAGEMENT OF SCARRING IN ENDOSCOPIC SURGERY

Arie Rosen, MD

Clinical associate professor, Otolaryngology UMDNJ, New Jersey Medical School/ Attending physician, Hackensack University Hospital, Hackensack (NJ), USA

Surgery for acquired or congenital strictures in the upper airway (UAW) or any other tubular structure in the body is challenging. Despite new endoscopic techniques, it continues to be associated with a high recurrence rate and subsequent stricture. The fundamental predicament in treating UAW scarring/ stenosis is how to effectively excise scar tissue without creating additional injury, inevitably triggering fibroblast proliferation, collagen deposition and fibrosis-re stenosis.

Topical Mitomycin C (MMC) application has been employed over the last few years with ever increasing popularity as an adjunct for prevention of scaring in endoscopic UAW procedures. This presentation will review the unique anti fibroblastic effects of MMC, current knowledge and indications for use of MMC in endoscopic UAW surgery and possible future indications for its use.

ENDOSCOPIC TREATMENT OF HYPOPHARYNGEAL-ZENKER DIVERVICULUM

Arie Rosen, MD

Clinical associate professor, Otolaryngology UMDNJ, New Jersey Medical School/ Attending physician, Hackensack University Hospital, Hackensack (NJ), USA

Zenker diverticulum is an out-pouching of hypopharyngeal mucosa through the posterior pharyngeal wall. It causes regurgitation of food, dysphagia

and eventually malnutrition. The condition is often identified in the elderly, medically frail and nutritionally depleted patients. Surgery for Zenker diverticulum has evolved from various open and endoscopic procedures throughout most of the 20th century, to the current minimally invasive endoscopic stapling which has been introduced in the early 90's. It has been since popularized in Europe and the US. It is a safe and effective procedure; it requires a short anesthesia and a short hospital stay. Patients can resume oral diet shortly after the procedure. However, the procedure has limitations and it requires special equipment. The author's experience with the procedure and review of the literature will be discussed.

INNOVATIVE CONCEPTS AND PROCEDURES IN PEDIATRIC ENDOSCOPICAL SURGERY

Klaus Schaarschmidt, MD

Department of Pediatric Surgery, HELIOS Klinikum Berlin-Buch, Germany

Basic pediatric diagnostic and operative laparoscopy is now used in many European Pediatric Surgical centres. Thoracoscopy and advanced laparoscopic or retroperitoneoscopic procedures are still limited to a small number of European Reference Centres for pediatric endoscopic surgery.

The scope of advanced pediatric and particularly neonatal laparoscopy is highly dependent on the individual experience of the team and on the technical equipment of the hospital, high definition 3 Chip digital camera, second camera, two HDTV monitors, Ultrasound scissors, water jet dissectors and high frequency sealing, argon beamer, 5 mm sets of various lengths, and a 2,7mm infant set, and heatable as well as humidified inflators and a laparoscopic training lab for specific phases of difficult operations are highly desirable.

Since 1991 our group explored and extended the scope of advanced pediatric endoscopic surgery accumulating an experience of 2129 minimally invasive pediatric operations in pediatric and adolescent surgery of the abdomen, thorax and retroperitoneum and introducing multiple international and European novel techniques.

Apart from developing and applying new laparoscopic techniques like splenectomy without staples and subtotal laparoscopic splenectomy in 116 children down to an age of 1 year, sutureless intraabdominal compression anastomosis in 28 patients with Crohn's disease or the first laparoscopic repair of imperforate anus in 1995 hybrid techniques are incre-

asingly used. That is the combination of several endoscopic modalities like colonoscopy plus laparoscopy for rectal perforation, cystoscopy and retroperitoneoscopy for renal or ureteric calculi. Moreover esophagoscopy/gastrosocopy plus laparoscopy proved exceedingly useful for 119 children with laparoscopic Thal repair of gastroesophageal reflux or Achalasia particularly for cases with multiple previous operations in other centers and for complex esophageal reconstructions. Endoscopic resections of increasingly large abdominal and tumours are possible wherever they are oncologically justified.

In thoracoscopy Hybrid techniques include bronchoscopy plus thoracoscopy for our new technique of thoracoscopic aortopericardiosternotomy for life-threatening tracheomalacia addition but also but also a combination of endoscopic and open technique for the worldwide first minimal access repair for pectus carinatum applied in 46 patients so far based on our extensive experience of 436 minimal access repairs of pectus excavatum including multiple improvements of the original Nuss technique. Finally the technique is increasingly applied for congenital malformations like thoracoscopic repair of congenital diaphragmatic hernia or thoracoscopic anastomosis of esophageal atresia in the newborn.

This experience amounts to one of the earliest and largest European in advanced endoscopic Pediatric Surgery.

PARALLELS BETWEEN AIR FLIGHT AND SURGERY

*Carsten Schmidt
Lufthansa, Austria*

On first sight, the work of pilots and surgeons seems to be very different. But it may well be compared: both groups are influenced by a similar variety of input factors; a number of professionals must come together to perform multiple and complex tasks in a noisy and cluttered environment. Activities must be coordinated and adding to the complexity of the environment, the condition of the patients is as highly variable as the cockpit crew's workload. Medical catastrophes also come under investigation, but not as publicly or intensively as air disasters. For example 70% of incidents in anesthesia like in aviation are due to the human error.

Around 1988, first major airlines began training their crews in "Crew Resource Management" (CRM) to reduce this human error and to reduce

risks in their daily operation. This CRM training has become the fundamental base for a safe airline operation. The training includes everybody involved in the process of flight.

Looking at the human error, we can evaluate different types of errors being made by different people in the hierarchy. The captain or senior has problems with taking the right decision while the copilot or the assistant has his problems with being assertive. The combination of both error-types is fatal. The good news: it can very well be trained.

We will now only look at the captains or seniors problem of taking a good decision. Major airlines use a so called "FORDEC-model". FORDEC stands for

- F** = **FACTS**: collecting facts
- O** = **OPTIONS**: looking for different options
- R** = **RISKS & BENEFITS**: evaluating the risks and benefits of each option mentioned above
- D** = **DECISION**: taking the decision by choosing the best option
- E** = **EXECUTION**: execute the decision
- C** = Check whether the decision is still correct in the changing environment

A structured, sometimes time consuming decision making process within a team contradicts people's desire to act and to lead in a superior way. And most of all, risks are often judged wrongly by individuals. Talking about the problem of individual risk evaluation, we have to talk about the probability of a fatal accident. Lufthansa's target value of course is the "zero accident rate". Approaching this value, the risk of a fatal crash must be far below 10-7 incidents per flight to have less than one accident every 15 years. The problem mentioned above is: nobody has a feeling for a 10-7 risk.

Taking the right decision means considering a FORDEC including the whole team. The required safety margin does not correspond to our daily and individually felt risks. Being old age and having a lot of experience, knowing you took the right decision a hundred times only means a safety level of 10-2.

A structured decision making process is one way to a safer operation in any high risk environment. This should be trained on regular bases as part of a CRM training. With this training, we will reach safety levels which are far below our own subjectively felt risk-threshold.

MINIMAL INVASIVE TREATMENT OF THORACOLUMBAL BURST FRACTURES

Schmidt J, Teßmann UJ

HELIOS Klinikum Berlin-Buch, Berlin, Germany

INTRODUCTION:

From the biomechanical view spine fractures has to be treated dorso-ventrally if they are accompanied with a tear of the vertebral disc. The AO-classification relates to those collateral injuries. In these cases, we have to resect the vertebral disc and ankylose this segment. In the last 10 years, this procedure has been performed by left sided thoracotomy. In the last 2 years, vidoscopic assisted procedures have been established with an enormous advantage for the patients.

METHODS:

Since 2003, we treated 96 burst fractures of the thoracolumbal region using vidoscopic assisted operation. In 2 cases, we had to change during the operation to thoracotomy. In 82 cases, we worked out a monosegmental spondylodesis, 14 cases needed a bisegmental stabilisation. In the last cases, we supported our stabilisation with a ventral ankelstable osteosynthesis. As replacement for the vertebral disc, we used in all monosegmental treatments cortico-cancellous bone grafts from the pelvis. One of the greatest problems in this operation in the indirect view of the camera is the placement of the graft. So we developed a targeting tool (vertebrometer).

RESULTS:

In all cases, we achieved a proper position of the graft. There were no secondary neurological deficits. Thoracal drains were removed after 24 hours, after this all patients were mobilized. The patients could leave our hospital 10 days after treatment in average. The return to work was in average 4 month after treatment independently of the profession.

SUMMARY:

The vidoscopically assisted treatment of thoracolumbal burst fractures has an enormous advantage in spine surgery. The recovery of patients takes shorter time, the operation procedure is safer. The vertebrometer is the next step in the development of this method.

THE COMBINED LAPAROSCOPIC AND VAGINAL APPROACH IN GYNAECOLOGICAL MALIGNANCIES

Schneider A, Köhler C

Clinic of Gynecology, Charité Campus Benjamin Franklin, Berlin, Germany

Laparoscopic-assisted radical vaginal hysterectomy and radical trachelectomy are well standardized surgical procedures with low complication rates. By bloodless dissection and magnification via the laparoscope nerve-preserving techniques can be done which reduce significantly morbidity of bladder and bowel. Patients with cervical cancer of less than 4 cm Ø, histopathologic negative lymph nodes, and absence of hemovascular tumor-involvement are ideal candidates for surgical treatment alone by laparoscopic-assisted radical vaginal hysterectomy combined with transperitoneal lymphadenectomy. When radical hysterectomy type III is indicated this can be done in a nerve-sparing concept. Radical vaginal trachelectomy in combination with laparoscopic lymphadenectomy allows preservation of fertility with oncologic safety and good results for pregnancy and child.

Patients with endometrial cancer profit from a combined laparoscopic vaginal approach, especially in the presence of one of the following factors: co-morbidity by other medical conditions, weight of more than 80 kg, Quetelet-Index > 30, or age of more than 65 years. The early and late postoperative phase of these patients is significantly improved.

Thus, the combined laparoscopic vaginal approach should be mastered by every gynaecological oncologist who wants to offer the complete spectrum of treatment options to his patients.

THE TRANSPERITONEAL LYMPHADENECTOMY

Schneider A, Köhler C

Clinic of Gynecology, Charité Campus Benjamin Franklin, Berlin, Germany

Laparoscopic lymphadenectomy is a prerequisite for staging and treatment of patients with gynaecologic cancers. The learning curve for pelvic lymphadenectomy is short, as opposed to paraaortic lymphadenectomy where it is long. The number of removed pelvic lymph nodes and the duration of the procedure are independent of the Body-Mass-Index. Following standardization of the technique, no severe intraoperative complications are encountered. In patients with cervical cancer < 2 cm Ø the sentinel

lymph node concept is associated with high sensitivity and a low rate of false-negatives. Detection of circulating tumor cells in sentinel lymph nodes using HPV-messenger RNA as a marker is currently evaluated in its potential as a prognostic marker. Transperitoneal lymphadenectomy is an essential prerequisite for staging of patients with invasive cervical cancer in order to select an individualized and optimal therapeutic strategy. Patients with negative lymph nodes are candidates for primary chemoradiation. Debulking of tumor-involved lymph nodes in the pelvic and/or paraaortic area is associated with improved survival. Laparoscopic evaluation of the lymph node status leads to upstaging in up to 80% of the patients which are lymph node negative by conventional imaging techniques. Thus, laparoscopic lymph node staging should be integrated into the routine staging of patients with cervical cancer and replace current FIGO-staging.

In patients with endometrial and early ovarian cancer pelvic and infrarenal paraaortic lymphadenectomy is feasible. Especially old, obese, and multi-morbid patients with endometrial cancer profit from laparoscopic lymphadenectomy with respect to early and late postoperative complications.

Laparoscopic lymphadenectomy is an essential part of staging and treatment of patients with cervical, endometrial and early ovarian cancer and has to be integrated in the armamentarium of gynecologic oncologists.

FOCUSED ULTRASOUND THERAPY: UTERINE FIBROIDS AND BEYOND

Elizabeth A. Stewart, MD, Clare M.C. Tempany, MD

Departments of Obstetrics, Gynecology and Reproductive Biology and Radiology, Brigham and Women's Hospital and Harvard Medical School, Boston, USA

Clinical treatment of uterine fibroids using high-intensity focused ultrasound (HIFU) or focused ultrasound surgery (FUS) is the fruition of many decades of research. FUS provides thermoablative therapy without placement of a probe into the target. MRI guidance provides clear imaging of both target and non-target tissues and provides real-time thermal feedback. The combination of these assets maximizes safety and efficacy and allows for surgical innovation while protecting human subjects.

Predictors of clinical success are beginning to be understood with this therapy. The mechanism of coagulative necrosis appears to avoid the post-

embolization syndrome seen following the ischemic necrosis of UAE and to allow for outpatient therapy with a rapid return to work.

For uterine fibroids, optimization of treatment protocols and investigation of the safety of FUS for women who desire fertility remain key issues. Additional applications for this technique include a number of benign and malignant diseases. Ultrasound-guided HIFU devices are also being studied and may provide additional approaches to gynecologic diseases. The non-invasive nature of FUS may lead to early intervention or prevention strategies in the future.

GENETICS AND FIBROIDS: THE FUTURE IS NOW

Elizabeth A. Stewart, MD, Cynthia C. Morton, Ph.D

Departments of Obstetrics, Gynecology and Reproductive Biology and Radiology, Brigham and Women's Hospital and Harvard Medical School, Boston, USA

The diversity of both clinical phenotype and karyotypic abnormalities in uterine fibroids (leiomyomas) suggests there may be many underlying genes influencing what is currently viewed as one disease process. The genetics of many complex diseases, including hypertension, diabetes and asthma, are receiving intense investigation and this should be our model for a research agenda.

For uterine fibroids, knowledge of the particular genes influencing disease is no longer a concern for the future. New information on the genetics of uterine fibroids is relevant to clinicians and patients because some genetic syndromes involving leiomyomas carry an increased risk of malignant disease both for the woman with fibroids and her family.

We are also beginning to understand some genotype/phenotype relationships for these prevalent tumors. It is also becoming clear that there is a distinct genetic risk for women of color, which likely explains their increased prevalence, and severity of disease.

A genome-wide scan such as the Finding Genes for Fibroid Study (www.fibroids.net) will be crucial in uncovering novel genes that predispose to this disease or cause growth acceleration. Knowledge of gene/environment interactions will allow novel prevention strategies for high-risk women in the future.

THE FAST TRACK CONCEPT IN COLON SURGERY

Albert Tuchmann, MD

Hospital Floridsdorf, Vienna, Austria

DEFINITION:

Fast track surgery is a concept of accelerated convalescence. The fundamentals of this new concept are patients' exact information and cooperation, perioperative analgesia with an epidural catheter, early postoperative oral feeding and early mobilisation.

PATIENTS:

142 patients (Feb.2004-Oct.2005) were treated with the fast track concept. We compared these patients to 167 patients with conventional care (operated between Jan.2002 and Dec.2003).

DIAGNOSES:

68 Carcinoma in the fast track group, 99 with conventional care.

Laparoscopic operations: 126 in the fast track group, 72 conventional care.

Hospital stay: 6 days (fast track) vs. 12 days (conventional care).

Surgical complications were equal in both groups, but non-surgical complications (lung, heart, intestinal paralysis) were reduced significantly: 4% fast track vs. 30% conventional care.

Mortality 2% vs. 7%.

The readmission rate was 7% in the fast track group.

SUMMARY:

The fast track concept was feasible in unselected colorectal patients. General complications (lung, heart, intestinal paralysis) were reduced significantly. The hospital stay was half compared to the conventional care patients.

LAPAROSCOPIC TREATMENT OF COLORECTAL CANCER

Albert Tuchmann, MD

Hospital Floridsdorf, Vienna, Austria

INTRODUCTION:

There is an ongoing controversy about laparoscopic operations of colorectal cancer due to technical difficulties, suspected local recurrence and portside metastases. Nevertheless, laparoscopic colorectal cancer surgery has been performed successfully in specialized centers.

PATIENTS:

Laparoscopic colon surgery for benign conditions (diverticulitis, adenoma) has been performed at Floridsdorf hospital since 1999. After these first experiences, the laparoscopic technique was applied to colorectal cancer cases: 93 patients were operated (53 colon carcinoma, 40 rectal carcinoma).

RESULTS:

7/93=6% anastomotic insufficiency. Wound complications 11/93=12%. Peritonitis caused by intestinal perforation 1, pulmonary embolism 1, myocardial infarction 1. Mortality 2/93=2%.

Follow up: Average follow-up was 12 months (1-49 m). There was no local recurrence and no portside metastasis. Liver metastases occurred in two patients, six out of seven patients died because of tumor progression.

SUMMARY:

Laparoscopic colorectal cancer surgery according to oncologic rules is possible (without technical difficulties). However, the long term results will have to be evaluated carefully.

ANESTHESIA FOR THE „NEW“ PATIENT HAVING LAPAROSCOPIC SURGERY: 5 YEARS FROM NOW

Klaus F. Wagner, MD

Clinic of Anesthesiology, University Luebeck, UKSH-CL, Germany

INTRODUCTION:

A focus of perioperative medicine in the near future will be the overweight and the old-age patients: bariatrics and the octogenarians. Patient care for them is challenging for both the surgeons and the anesthesiologists. This presentation will focus on the peculiarities of anesthesia for bariatric and old-age patients as well as the implications for team perioperative management.

DISCUSSION:

Difficult Intubation of bariatric patients can be expected if the skin-cricoid distance is more than 28 mm, though being overweight is not a risk factor predictive of a difficult intubation. Android body mass distribution is a risk factor for coronary heart disease and android stature in a bariatrics patient deserves more thorough preoperative cardiovascular assessment. Bariatrics with gynecoid body mass distribution on the other hand do not seem to have an increased incidence of coronary arteriosclerosis. In bariatric patients, apart from cardiovascular morbidity, pulmonary pathophysiology

and pharmacokinetics show important differences compared to normal patients. These issues will be addressed and their implications on the perioperative management will be discussed.

Demography has introduced and continues to introduce patients to surgical therapy who have been termed octogenarians (80+ years), nonagenarians (90+ years) and even centenarians (100+ years). Those will be the patients we will care for in the future. As stated for bariatric patients, old age patients have an number of pathophysiological characteristics. They most of all allude to the cardiovascular system and the cerebral function. Thus postoperative cognitive dysfunction is of particular concern in this patient group.

CONCLUSION:

While the anaesthetic of choice for the octogenarian has yet to be determined, the treatment team has to make every effort to approach this very important patient group to their hospital. Advancing care for the bariatric and the elderly patient will be a worthwhile and rewarding challenge of the future.

ANESTHESIA AND THE FUTURE OPERATIVE ENVIRONMENT FOR LAPAROSCOPIC SURGERY

Klaus F. Wagner, MD

Clinic of Anesthesiology, University Luebeck, UKSH-CL, Germany

INTRODUCTION:

Endoscopic, minimally invasive surgery is established and thriving in General Surgery, Gynaecology, Urology, and Otolaryngology. Anaesthesiology has adapted to the challenges of positioning, darkness and speed. Yet, the everyday operative environment encountered in most ORs is far from optimizing and simplifying surgical procedures. To deliverer the highest standard of care with best outcome and patient satisfaction; the future operative environment has to be integrated, simple and ergonomic. This lecture will present some ingredients of OR integration and OR ergonomics that allow for a „tasty“ operative environment.

DISCUSSION:

For many procedures endoscopic surgery outperforms open surgery. But several disadvantages are inherent to the endoscopic approach. The equipment is complicated and consists of many stand alone devices, ergonomics is if low priority, a high standard of training is mandatory, and

patient through is not always high. To overcome these obstacles the project FUSION was started. FUSION aims to analyse shortcomings of the current OR setting for minimally invasive surgery and to design an operative cockpit corroborating diagnostics, superior endoscopic instruments, and an integrated anaesthesia working environment. While the design of more ergonomic instruments is a fruitful endeavour collaborating with respective companies, the question of which and how many diagnostic techniques have to be available in the OR remains unanswered. The impact of a decision to integrate an MRI into the OR has marked implications for the surgical equipment as well as the anaesthetic machinery and is extremely costly. Thus, currently MRI in the OR is not favoured. Still, the 3D images generated by MRI are gold standard. An alternative approach is the integration of the data of various diagnostic methods (X-ray, ultrasound, PET, etc.) into a 3D synoptic image visualized in the OR. But the generation of this synoptic image is a huge challenge to image processing and system interfaces. To further complicate the matter, the patient's digital medical records should to be available in the integrated, simple and ergonomic OR of the future.

CONCLUSION:

„The spirit is willing but the flesh is weak“. The future operative environment for laparoscopic surgery is starting to emerge but lots of work remains to be done until ergonomic simplicity and integration are achieved.

CRYOMYOLYSIS AND LAPAROSCOPY

Errico Zupi, MD

University of Rome ,Tor Vergata', Rome, Italy

OBJECTIVE:

To evaluate the long-term effectiveness of laparoscopic cryomyolysis as a minimally invasive technique for the treatment of symptomatic uterine myomas in menstruating women.

DESIGN:

Open one arm pilot study

SETTING:

University affiliated public hospital

PATIENTS:

20 patients with symptomatic uterine fibroids were treated with directed cryomyolysis. All had complaints of either abnormal bleeding and/or pelvic pain/pressure and/or urinary frequency. Myoma diameters varied from 4 to 10 cm..

INTERVENTION:

One year follow-up after laparoscopic directed cryomyolysis,

MEASUREMENT AND MAIN RESULTS:

Laparoscopic cryomyolysis was performed using the Her Option™ Cryo-ablation Unit. (American Medical Systems ,Minneapolis, Minnesota, USA) Patients were evaluated at one, three, 6, 9, and 12 months postoperative. Power Color Doppler was performed pre and post operative to demonstrate the effectiveness of the technique in reducing or eliminating the primary blood supply of as well documenting regression of the myomas.

All patients reported a high rate of satisfaction with the treatment including absence of symptoms after 12 months from the surgery, with no bleeding, no myomas related symptoms, comparable to patients who underwent hysterectomy.

Mean shrinkage of fibroids volume increased until 9 months ($59.5\% \pm 13.2\%$) reaching a steady mean volume reduction around 60 % ($61.9\% \pm 11.9\%$) at 12 months from surgery.

CONCLUSIONS:

Directed Laparoscopic cryomyolysis appears to be an effective and safe technique in providing rapid symptom relief and at least 12 months effectiveness in the treatment of symptomatic uterine leiomyomas.

LAPAROSCOPIC APPROACH TO DERMOID CYSTS: COMBINED SURGICAL TECHNIQUE AND ULTRASONOGRAPHIC EVALUATION OF RESIDUAL FUNCTIONING OVARIAN TISSUE

Errico Zupi, MD

University of Rome ,Tor Vergata', Rome, Italy

Dermoid cysts arise from germ cell after the first meiotic division and account for 5% to 25% of all ovarian cysts, making them one of the most common ovarian neoplasm in women in the reproductive age. These be-

nign tumors are most frequently diagnosed in young women and may interfere with fertility or cause pain, adnexal torsion or rupture. Advances in endoscopic surgery permit laparoscopic tretment of ovarian cysts that previously required laparotomy and at the present laparoscopic management of ovarian dermoid cysts is the technique of choice.

OBJECTIVE:

Estimate how and if laparoscopic removal of ovarian dermoid cysts is a tissue - sparing procedure

DESIGN:

Prospective study

SETTING:

University-associated hospital

INTERVENTION:

Laparoscopic removal of ovarian dermoid cysts by a combination of hydrodissection and blunt dissection, and transvaginal sonographic evaluation of residual ovarian tissue.

MEASUREMENTS AND MAIN RESULTS:

Within 1 week before surgery all recruited patients underwent to TVS evaluation of ovarian volume, size, and morphology of dermoid cysts and measurement of surrounding ovarian cortex. Mean cyst diameter was 5,5+/- 2,2 cm (range 2,1-15,0): Within 6 to 12 months after laparoscopic excision, TVS measurements of residual ovarian tissue were obtained. Ovarian residual cortex surrounding the cyst was not visibile at TVS in 24 ovaries, whereas in 56 ovaries residual tissue volume was greater than 3 cm³ after laparoscopic excision.

CONCLUSION:

We propose laparoscopic removal of dermoid cysts by combining hydrodissection and blunt dissection with maximal tissue sparing, even when the cysts seem to fill the ovary and no surrounding ovarian cortex can be seen on ultrasound.

HYSTEROSCOPIC ENDOMETRIAL RESECTION VERSUS LAPAROSCOPIC SUPRACERVICAL HYSTERECTOMY FOR MENORRHAGIA: A PROSPECTIVE RANDOMIZED TRIAL

Errico Zupi, MD

University of Rome ,Tor Vergata', Rome, Italy

OBJECTIVE:

This study was undertaken to compare the relative efficiency and safety of hysteroscopic endometrial resection and laparoscopic supracervical hysterectomy in the treatment of abnormal uterine bleeding.

STUDY DESIGN:

One hundred eighty-one patients suffering from menometrorrhagia and not responding to medical treatment agreed to be randomized to either laparoscopic supracervical hysterectomy or hysteroscopic endometrial ablation. They were monitored for 2 years to evaluate perioperative and post-operative outcomes, resolution of symptoms, and patient satisfaction.

RESULTS:

Duration of hospitalization, period of convalescence, perioperative complications, and resumption of normal activity were similar between the two groups. Operative time was significantly shorter in the hysteroscopic group, but patient satisfaction was significantly higher in the laparoscopic group.

CONCLUSION:

For the treatment of menorrhagia, hysterectomy has the distinct advantage of being curative but the disadvantage of being more invasive than the hysteroscopic approach. However, laparoscopic supracervical hysterectomy preserves the curative effect of hysterectomy without its increased surgical invasiveness, as suggested by the current study.

Useful information

Organisation of the congress:

Clémence Delmas

Sabine Wolf

The New European Surgical Academy (NESA)

Karower Strasse 11/214

D-13125 Berlin, Germany

Phone: +49 (0)30 9401-2993

Fax: +49 (0)30 9401-2430

www.nesacademy.org

Congress Office:

INTERPLAN

Congress, Meeting & Event Management AG

Mrs. Johanna Krause

Albert-Rosshaupter-Strasse 65

D-81369 Munich, Germany

Phone: +49 (0)89 5482 3411

Fax: +49 (0)89 5482 3443

Email: nesa06@interplan.de

www.interplan.de

Hilton Hotel Berlin

Mohrenstrasse 30

D-10117 Berlin, Germany

Phone: +49 (0)30 2023-0

www.hilton.com

Layout:

Jürgen Dachner

Wiltbergstrasse 50

D-13125 Berlin, Germany

The New European Surgical Academy (NESA)

Karower Strasse 11/214

D-13125 Berlin, Germany

Phone: +49 (0)30 9401-2993

Fax: +49 (0)30 9401-2430

www.nesacademy.org